

ALTERATIONS OF THYROID MORPHOLOGY AND FUNCTION AFTER LONG-TERM EXPOSURE TO LOW DOSES OF ENDOCRINE DISRUPTOR DICHLORODIPHENYLTRICHLOROETHANE

UDC 616.44.001.6–008:57.055:615.015
Received 28.04.2014



V.V. Yaglov, D.Med.Sc., Professor, Principal Research Worker of Endocrine System Development Laboratory;
N.V. Yaglova, D.Med.Sc., Head of Endocrine System Development Laboratory

Scientific Research Institute of Human Morphology of the Russian Academy of Medical Science, Tzurupa St., 3,
Moscow, Russian Federation, 117418

The aim of the investigation was to evaluate changes in thyroid morphology and function after different long-term exposure to low doses of endocrine disruptor dichlorodiphenyltrichloroethane (DDT) under the maximum permissible levels in food products.

Materials and Methods. The experiment was performed on adult male Wistar rats (n=62). Drinking water was substituted for water solution of o,p-DDT 20 and 80 µg/L. Mean daily consumption of DDT was 1.89±0.86 and 7.77±0.17 µg/kg body weight, respectively. Rat serum thyroid hormone content and histology of the thyroid glands were studied after 6 and 10 weeks of exposure to DDT.

Results. 6-week exposure to DDT caused inhibition of thyroid function followed by reactive increase of thyroid stimulating hormone secretion and triiodothyronine production. These symptoms were similar to those of early stage of iodine deficiency. Restoration of rat thyroid status after 10 weeks of exposure was achieved due to diffuse microfollicular transformation of thyroid parenchyma.

Conclusion. Exposure to low doses of DDT inhibits thyroid function. Reactive increase of thyroid hormone production after exposure to DDT and in iodine deficiency are alike, but early changes in thyroid histology are different. Long-term exposure to DDT is supposed to aggravate iodine deficiency and to be a risk factor of thyroid tumors.

Key words: endocrine disruptor; dichlorodiphenyltrichloroethane; thyroid; thyroid hormones.

Investigation of the effect of endocrine disruptors on organ and system functioning is one of the priority problems of clinical and fundamental medicine [1]. Endocrine disruptors are exogenous substances, contained in soil, water, air, foodstuff, and some industrial items, which, entering the organism, exert hormone-like effects, impairing homeostatic mechanisms of regulating vital activity of living organisms by endogenous hormones [1, 2]. Pesticide dichlorodiphenyltrichloroethane (DDT) is referred to the most common endocrine disruptors, contained in the environment [2]. If products with its content are being consumed for a long time, it is capable of accumulating in the organs of human beings and animals: in the liver, brain, thymus, testicles, and to the most extent, in the adipose tissue [1, 2].

The aim of the investigation was to study changes in thyroid morphology and function after a long-term exposure to low doses of endocrine disruptor dichlorodiphenyltrichloroethane (DDT) *in vivo*.

Materials and Methods. The investigation was performed on male Wistar rats (n=64) with a body weight of 80–100 g. A consumed DDT dose was calculated according to the requirements to determining low doses [3], taking into consideration threshold values of low

doses for DDT (50 µg/kg/day) [4], and norms of DDT content in food products in the Russian Federation [5].

Animals of the experimental groups were given solutions of o,p-DDT (Sigma, USA) with a concentration of 20 µg/L (n=22) and 80 µg/L (n=22) during 6 and 10 weeks. Daily average consumption of DDT amounted to 1.89±0.86 and 7.77±0.17 µg, respectively. Animals from the control group (n=20) received tap water. Absence of DDT, its metabolites and related chlororganic compounds in the tap water and animal food was confirmed by gas-liquid chromatography. Animals were withdrawn from the experiment after 6 and 10 weeks by the overdose of zoletyl.

The experiment was approved by the Ethics Committee of Scientific Research Institute of Human Morphology of the Russian Academy of Medical Sciences, and was carried out in accordance with the Rules of conducting the works using experimental animals, approved by Order of the Ministry of Health of the USSR No.577 of 8 August 1977, and by ethical principles, established by European Convention for Protection of Vertebrate Animals used for Experimental and other Scientific Purposes (passed in Strasbourg on 18 March 1986, and confirmed in Strasbourg on 15 June 2006).

For contacts: Yaglova Nataliya Valentinovna, e-mail: yaglova@mail.ru

Concentrations of thyrotropic hormone (TTH), total thyroxine (T_4), total triiodothyronine (T_3), free triiodothyronine (fT_3) were determined in blood serum by means of enzyme-linked immunosorbent assay using commercial test kits (Cusabio Biotech, China; Monobind, USA). A proportion of concentration fT_4 and fT_3 of T_4 and T_3 concentration ($\%fT_4$ and $\%fT_3$), and fT_3/fT_4 ratio were counted. Thyroid gland (TG) was fixed in Bouin solution, and after the standard procedure paraffin sections were prepared. Histologic TG preparations were stained with hematoxylin and eosin, PAS staining method was also used. Preparations were examined by light microscopy and computed morphometry methods using ImageScope program (Leica Microsystems, Austria). Dimensions of follicles, the height of follicular thyrocytes and their nucleus sizes, the content of colloid in the follicle cavities, and Brown index (ratio of a follicle diameter to the double height of follicular thyrocytes), which is an indicator of colloid retention were determined. Investigations were performed separately in the central and peripheral lobe zones, amounting to one third and two thirds of the lobe, respectively, taking into account a regional structure of the rat's TG lobes [6].

Statistical processing was made by means of applied program package Statistica 7.0 (Statsoft Inc. USA). Central tendencies and dispersion of quantitative signs, having approximately normal distribution, were described as mean value M and standard error of mean m . On their basis, conversion of absolute values to the relative ones was made, taking values of the control group for 1. Comparison of independent groups according to the quantitative sign was performed using Student t -criterion, taking into consideration values of Levene's criterion on the equality of variances, and Mann-Whitney criterion as well. Differences were regarded as statistically significant when $p < 0.01$.

Results

After 6 weeks of DDT consumption in the dose of $1.89 \pm 0.86 \mu\text{g/kg/day}$ increase of T_4 concentration and a less marked elevation of fT_4 in the systemic bloodstream of the rats were noted. Proportion of fT_4 did not change compared to the values of the control group. A significant rise of T_3 , fT_3 and $\%fT_3$ and decrease of TTH secretion by hypophysis (Fig. 1) were found.

In the rats with the consumption of DDT in the dose of $7.77 \pm 0.17 \mu\text{g/kg/day}$ increase of T_4 concentration was also noted. Of special interest was a lower content of T_3 , which did not differ from the values of the control group, whereas concentration of fT_3 was higher than in the control group but, at the same time, lower in the group of rats, consuming DDT in the lower dose. Just as in the previous group, an imbalance in the ratio of fT_3/fT_4 in the direction of fT_3 predominance was observed.

Histological investigations of TG showed differences in the values of experimental and control groups of rats.

After 6 weeks parenchyma of TG in the rats of the control group had a typical follicular structure. In the

parenchyma of TG lobes central and peripheral zones were distinguished. Follicles in the peripheral zone were 2.5 as large as in the central one. Follicular thyrocytes were more often of a cylindrical and rarer of a cubic form. Intrafollicular colloid was thick, characterized by a distinctly positive PAS reaction, partly resorbed. In the central zone of the lobes the height of the follicular thyrocytes and the dimensions of their nuclei corresponded to the values in the peripheral zone. The content of intrafollicular colloid in the follicle lumen was higher. Colloid was looser, resorption vacuoles were encountered. Stroma was characterized by moderate development. Blood filling of the vessels was non-uniform.

After 6 weeks of consuming DDT in the dose of $1.89 \pm 0.86 \mu\text{g/kg/day}$ regional changes were observed in the TG parenchyma of the rats. In the peripheral zone of the lobes increase of the follicle size and Brown index took place, however, an essential reduction of the follicular thyrocyte heights was not observed (Fig. 2, a). Insignificant decrease of colloid content in the follicle lumens was noted. In the central zone of the lobes decrease of the follicle size and elevation of the follicle thyrocyte heights occurred (Fig. 2, b). Thyrocyte nuclei dimensions slightly increased just as in the peripheral zones of the lobes. Reduction of the colloidal content in the follicle lumens took place in the same way. Changes of the microcirculatory bloodstream were not found.

When large doses of DDT were consumed — $7.77 \pm 0.17 \mu\text{g/kg}$ — the same, though more marked changes were established in the peripheral TG lobes, except for the reduction of thyrocyte nuclei dimensions. In the central zones of the lobes in contrast to the rats, consuming a less DDT dose, follicles increased in size, Brown index rose. A decrease of the colloid portion was less significant. Follicle thyrocyte height became less, thyrocyte nuclei dimensions reduced. Changes of the microcirculatory bloodstream were not revealed in comparison with the control group.

After 10 weeks of consuming DDT in the dose of $1.89 \pm 0.86 \mu\text{g/kg/day}$ concentration of T_4 in the rat serum slightly reduced in comparison with the previous period of investigation and statistically did not differ significantly from the values of the control group for the given period of investigation. Concentration of fT_4 , on the contrary, decreased essentially compared to the previous investigation period and practically became equal to the values of the control group. And because of it the portion of fT_4 reduced statistically significantly in comparison with the previous investigation period and with the values of the control group as well. Lowering of fT_3 content and its proportion of the total quantity of T_3 was noted. These values were also statistically significantly lower compared to the values of the control group for the given period of investigation. Reduction of thyroid hormone production resulted in the rise of TTH secretion and its content in the blood serum (See Fig. 1).

Fig. 1. Changes of the relative values of thyroid status of the rats, consumed DDT during 6 and 10 weeks. Values of the control group were taken for 1. * — statistically significant differences from the control group, ^ — differences from the previous period of investigation

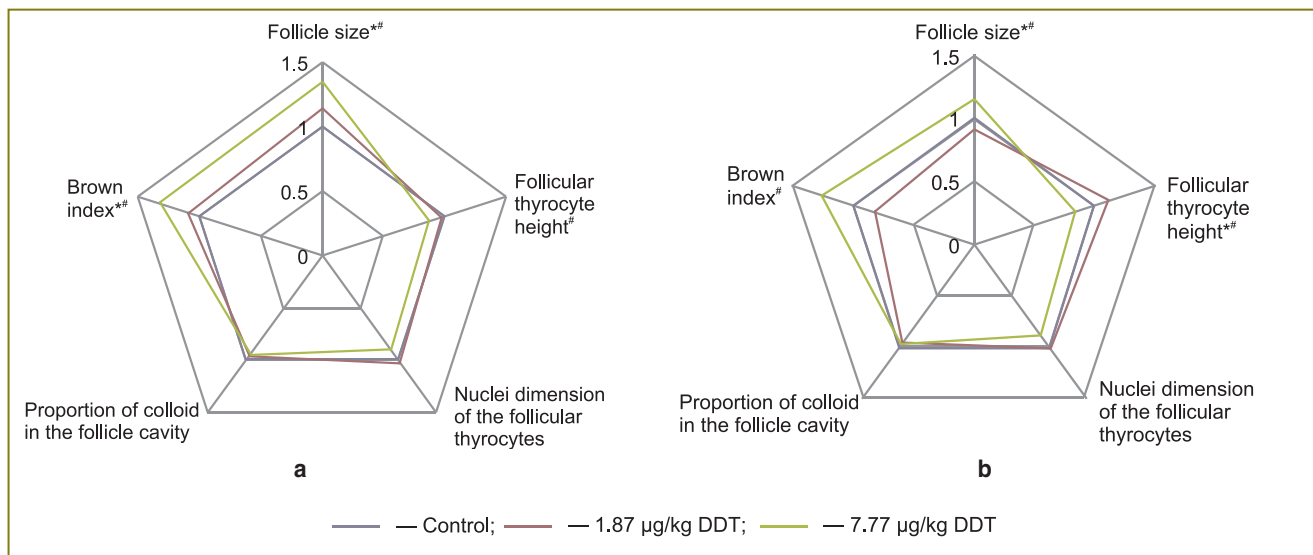
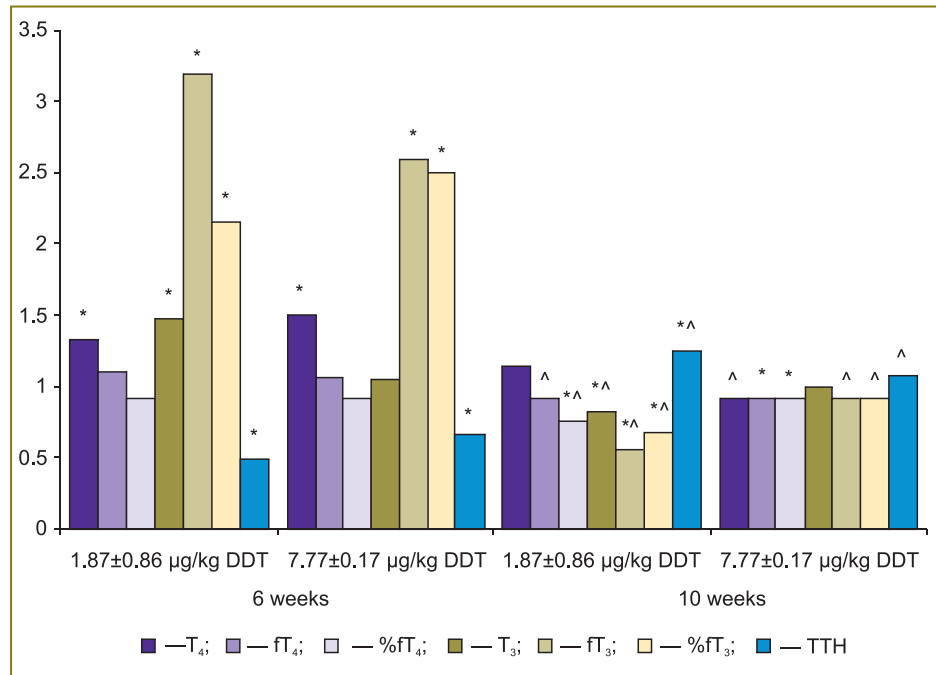


Fig. 2. Changes of morphometric values of peripheral (a) and central (b) zones of the thyroid gland lobes of the rats, having consumed DDT during 6 weeks. Values of the control group are taken for 1. * — statistically significant differences of the group, consumed DDT in the dose of 1.87±0.86 µg/kg/day, and the control group; # — of the group, consumed DDT in the dose of 7.77±0.17 µg/kg/day, and the control group

In the rats with DDT consumption in the dose of 7.77±0.17 µg/kg/day changes of the thyroid profile of the blood serum corresponded to the changes in the experimental group, which consumed DDT in the lower dose, in contrast to the data in the previous investigation period. Reduction of concentration of T₄ and T₃ and its free fractions was noted. Decrease of fT₄ and the proportion of fT₄ were more marked, resulting in the lower values than in the control group. Content of T₃ and fT₃ in the systemic bloodstream did not differ from the values of the control group.

Examination of the TG histological preparations of the rats in the control groups revealed some changes in comparison with the previous investigation period. Intensification of differences in the structure of the peripheral and central zones of the TG lobes was observed. In the peripheral zone of the lobes a 1.5-fold increase of follicle sizes, reduction of follicular thyrocyte heights, rise of Brown index were noted as compared to the previous period of investigation. Intrafollicular colloid was characterized by a high density, and distinctly positive PAS reaction. In some follicles colloid had a

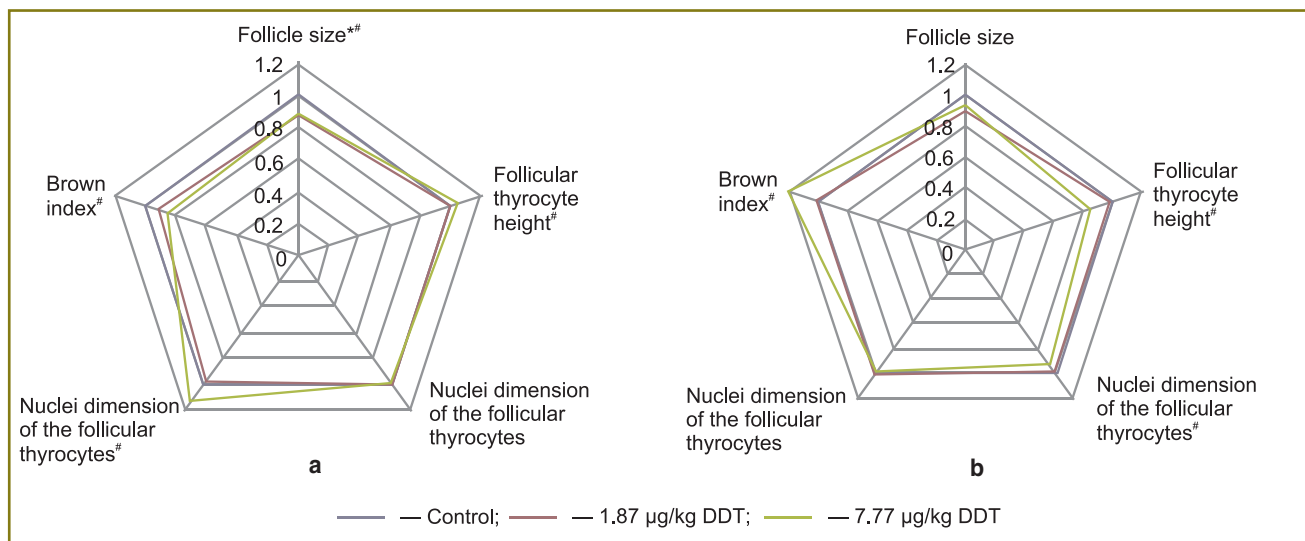


Fig. 3. Changes of morphometric values of peripheral (a) and central (b) zones of the thyroid gland lobes of the rats, having consumed DDT during 10 weeks. Values of the control group are taken for 1. * — statistically significant differences of the group, consumed DDT in the dose of $1.87 \pm 0.86 \mu\text{g/kg/day}$, and the control group; # — of the group, consumed DDT in the dose of $7.77 \pm 0.17 \mu\text{g/kg/day}$, and the control group

scallop outline, resorption vacuoles were also found. In the central zone of the lobes considerable changes were not established.

After 10 weeks of DDT consumption in the dose of $1.89 \pm 0.86 \mu\text{g/kg/day}$ morpho-dynamic processes similar to those of the control group were noted. In the peripheral zone of the lobes increase of follicle size, and rise of the Brown index occurred (Fig. 3, a). However, both values were statistically significantly less than in the control group of the corresponding investigation period. Follicles had oval, frequently irregular form. As a rule, the form of follicular thyrocytes was cubic. Their nuclei enlarged in their size in comparison with the previous period of investigation, and had round and oval form with a long axis oriented perpendicularly to the basis of the cell. Follicular lumens were filled with a dense colloid, showing distinctly positive PAS reaction. In many follicles colloid had a scallop outline, resorption vacuoles were often encountered. In the central zone of the lobes, the sizes of the follicles did not change. Relative to the previous investigation period, reduction of the follicular thyrocyte height was observed. Parenchyma of the central zone of the lobes did not differ in its structure from the control group of the animals (Fig. 3, b). There were no differences in the stroma as well.

In contrast to the previous investigation period, dramatic changes occurred in the TG parenchyma of the rats, consuming DDT in the dose of $7.77 \pm 0.17 \mu\text{g/kg/day}$. In the peripheral zone of the lobes the height of the follicular thyrocytes and dimensions of their nuclei enlarged, the content of colloid increased. The follicle sizes did not change and were less than in the animals of the control group. Follicular thyrocytes had a

cylindrical form and the height larger than in the previous investigation period, in the control group and also in the group, consuming DDT in a lower dose. The sizes of the follicular thyrocyte nuclei corresponded to the values of the control group, and were smaller than in the comparison group. Relative to the previous period of investigation, colloid content in the follicles elevated. It reached maximal values compared to the control group and the group with a lower DDT dose. Colloid filled the follicle lumen practically completely, was characterized by a high density, and distinctly positive PAS reaction. Resorption vacuoles were encountered along the margins. In the central zone of the lobes the reduction of the follicle sizes was observed in contrast to the control group and the comparison group (See Fig. 3, b).

The second special feature was preservation of the follicular thyrocyte height as it was in the previous investigation period. Thus, this value was significantly less than in the control animals and in those consuming a lower DDT dose. The third feature was statistically significant increase of follicular thyrocyte nuclei sizes in comparison with the previous period, though they were smaller than in the control and comparison groups (See Fig. 3, b). Intrafollicular colloid was dense, resorption vacuoles were encountered rarer than in the control group.

Discussion. Alterations in the hormone production in various endocrine glands under the DDT action are described in a number of works [7, 8]. However, conclusions in regard to the influence of DDT on the production of thyroid hormones are, in many ways, contradictory. In individuals, exposed to different DDT doses, diminishing of T_4 production and elevation of T_3 production were noted, as well as absence of any

changes of thyroid status [9–12]. The investigation performed showed, that changes of thyroid hormone metabolism are of a two-phase character.

At the first stage intensification of T_4 production and a sharp enhancement of peripheral conversion of T_4 to T_3 is going on. This allows to conclude, that the effect of low DDT doses results in the disturbance of iodine transport into follicular thyrocytes and, respectively, in reactive dose-dependent increase of TTH, T_4 , and conversion of T_4 to T_3 , being in reciprocal dependence on the production of T_4 . Such changes of thyroid status are typical for early stages of endemic goiter, caused by iodine deficiency. Morphological changes, observed in the first phase, are the evidence of the reducing TG activity. Comparing changes occurring under the influence of various DDT doses, a linear relationship between the increase of disruptor dose and enlargement of follicle sizes, Brown index, diminishing of follicular thyrocyte heights and colloid in the follicle lumen is observed in the peripheral zone of the lobes. In the central zone similar dose-dependence was not established. Analysis of the structure of the TG lobe central zone, exposed to the two low DDT doses, revealed more rapid development of the changes, directed towards the increase of T_4 production by the gland: restructuring of the parenchyma, i.e. increase of the follicle number per area unit due to the reduction of their size, enlargement of the height of follicular thyrocytes and their nuclei, intensification of intrafollicular colloid resorption. In the group, consuming a larger dose, these changes were developing later and were not so evident.

In the second phase, relative normalization of thyroid status occurs owing to compensatory restructuring of the parenchyma, involving also peripheral areas of the TG lobes. In the later period, resorption of thyroglobulin by follicular thyrocytes becomes more intense in the peripheral zone of the lobes, while functioning of follicular thyrocytes in the central zone returns to norm. When larger DDT doses are consumed, compensatory restructuring of the parenchyma in the lobe central zones goes on slower and includes mainly resorption of thyroglobulin and activation of thyrocytes of the peripheral zone of the lobes.

Comparison of morphological TG changes under the action of DDT and in iodine deficiency shows availability of common features and differences as well. Relative deficiency of iodine is known to result in the changes of TG structure, running in two stages [13]. At the first stage, reactive increase of follicular thyrocyte height, reduction of follicle lumens and dilation of microcircular bloodstream vessels occur in the TG. These alterations are developing during 2–3 weeks. At the second stage, decrease of iodine metabolism in the TG and its compensatory hypoplasia take place. In men, rats mice follicles with epithelium, growing into the follicle cavity (Sanderson' polsters), formation of new microfollicles and follicles, lined with two-layer epithelium, appear in the

TG [13]. Examination of TG preparations after 6 weeks of DDT consumption did not find any obvious signs of its activation in the rats, consuming higher DDT dose. In the rats, consuming a lower dose, signs of the elevated functional activity of thyrocytes in the form of follicle size reduction and enlargement of follicular thyrocyte heights appeared only in the central zone of the lobes following 6 weeks. Dilation of the microcircular bloodstream vessels was not observed. At the second stage, a common feature of iodine deficiency states and DDT effect was the reduction of follicle sizes, i.e. increase of "the working surface" of the organ, but proliferation of follicular epithelium did not occur. Consequently, morphologic manifestations of the effect of disruptor low doses are less apparent despite of the significant changes of thyroid status. Thyroid status restores owing to the increase of the follicle quantity, that is, TG hyperplasia. This makes the risk of tumor development rather high, because hyperplastic processes in the TG, connected with iodine metabolism disorder, are characterized by their slow reversibility after reaching euthyroid state [14].

Conclusion. Long-term consumption of DDT low doses within the limits of maximally permissible levels of its content in food products and water leads to the consecutive morpho-functional changes of the thyroid gland, characterized by the reduction of its functional activity with intensification of synthesis of thyroid stimulating hormone, thyroxine and triiodothyronine, which are similar to the processes going on in the development of iodine deficiency, as well as to the subsequent diffuse microfollicular restructuring, providing restoration of euthyrosis.

Morphological alterations of the thyroid gland under the action of low doses of DDT have similarity with the changes in endemic goiter, but differ from them by a lower speed of developing reactive and compensatory changes, absence of the marked alterations of microcircular bloodstream, and less intensive proliferation of follicular epithelium.

The effect of low doses of DDT is necessary to consider as an aggravating factor of endemic goiter pathogenesis, increasing the risk of oncologic diseases of the thyroid gland.

Study Funding and Competing Interest. This study was performed according to the plan of the scientific research work of the Scientific Research Institute of Human Morphology of the Russian Academy of Medical Sciences, and there is no topic specific conflict of interest related to the authors of this study.

References

1. Diamanti-Kandarakis E., Bourguignon J.-P., Guidice L.C., Hauser R., Prins G.S., Soto A.M., et al. Endocrine-disrupting chemicals: an Endocrine Society scientific statement. *Endocr Rev* 2009 Jun; 30(4): 293–342, <http://dx.doi.org/10.1210/er.2009-0002>.
2. Yaglova N.V., Yaglov V.V. Endocrine disruptors are a

- novel direction of endocrinologic scientific investigation. *Vestnik RAMN* 2012; 3: 56–61.
3. *National Toxicology Program's report of the endocrine disruptors low dose peer review*. National Institute of Environmental Health Sciences, NIH National Toxicology Program. 2001.
 4. Vandenberg L.N., Colborn T., Hayes T.B., Heindel J.J., Jacobs D.R. Jr., Lee D.-H., Shioda T., Soto A.M., vom Saal F.S., Welshons W.V., Zoeller R.T., Myers J.P. Hormones and endocrine-disrupting chemicals: low-dose effects and nonmonotonic dose responses. *Endocr Rev* 2012; 33(3): 378–455, <http://dx.doi.org/10.1210/er.2011-1050>.
 5. *Gigienicheskie trebovaniya bezopasnosti i pishchevaya tsennosti pishchevykh produktov*. SanPin 2.3.2.1078-01 [Hygienic requirements to safety and nutritional value of food products. Sanitary rules and norms 2.3.2.1078-01]. 2008.
 6. Yaglova N.V. Impairments of the secretory cycle of follicular thyrocytes and their correction by thyroid-stimulating hormone in experimental syndrome of nonthyroid diseases. *Bulleten' eksperimental'noj biologii i mediciny* 2011; 152(8): 215–219.
 7. Orton F., Rosivatz E., Scholze V., Kortenramp A. Widely used pesticides with previously unknown endocrine activity revealed as in vitro antiandrogenes. *Environ Health Perspect* 2011; 119(6): 794–800, <http://dx.doi.org/10.1289/ehp.1002895>.
 8. Lacroix M., Hontela A. The organochlorine o,p'-DDT disrupts the adrenal steroidogenic signaling pathway in rainbow trout (*Oncorhynchus mykiss*). *Toxicol Appl Pharmacol* 2003; 190(3): 197–205, [http://dx.doi.org/10.1016/S0041-008X\(03\)00168-6](http://dx.doi.org/10.1016/S0041-008X(03)00168-6).
 9. Scollon E., Carr J., Cobb C. The effect of flight. Fasting and p,p'-DDT on thyroid hormones and corticosterone in Gambel's white-crowned sparrow, *Zonotrichia leucophrys gambelli*. *Comp Biochem Physiol C Toxicol Pharmacol* 2004; 137(2): 179–189.
 10. Schell L.M., Gallo M.V., Denham M., Ravenscroft J., DeCaproi A.P., Carpenter D.O. Relationship of thyroid hormone levels to levels of polychlorinated biphenyls, lead, p,p'-DDE, and others toxicants in Akwesasne Mohawk youth. *Environ Health Perspect* 2008; 116(6): 806–813, <http://dx.doi.org/10.1289/ehp.10490>.
 11. Langer P. The impacts of organochlorines and other persistent on thyroid and metabolic health. *Front Neuroendocrinol* 2010; 31(4): 497–518, <http://dx.doi.org/10.1016/j.yfrne.2010.08.001>.
 12. Meeker J., Altshul L., Hauser R., Serum PCBs, p,p'-DDE and HCB predict thyroid hormone levels in men. *Environ Res* 2007; 104(2): 296–304, <http://dx.doi.org/10.1016/j.envres.2006.11.007>.
 13. Denef J.-F., Haumont S., Beckers C. Morphological changes in mice thyroid induced by iodine deficiency. *Virchows Arch B Cell Path* 1980; 32: 191–199.
 14. Khmel'nitskiy O.K. *Tsitologicheskaya i gistologicheskaya diagnostika zabolevaniy shchitovidnoy zhelezy* [Cytologic and histologic diagnosis of thyroid gland diseases]. Saint Petersburg: SOTIS; 2002; 288 p.