

A CASE OF INTRALUMINAL ENDOSCOPIC SUTURING OF GASTRIC PERFORATION

UDC 616.33–089.81/.86
Received 27.01.2014



S.V. Kantsevoy, PhD, M.D., Director of the Center for Therapeutic Endoscopy¹; Clinical Professor²;
A.A. Mitrakov, Head of Endoscopy Department³;
A.V. Peshkin, Oncologist, 2nd Oncology Department³

¹Institute for Digestive Health and Liver Disease at Mercy Medical Center, 301 St. Paul Place, Baltimore, Maryland 21202, USA;

²University of Maryland School of Medicine, 655 West Baltimore St., Baltimore, Maryland 21201-1559, USA;

³Nizhny Novgorod Regional Oncological Dispensary, Ankudinovskoye shosse, 1, Nizhny Novgorod, Russian Federation, 603081

Recent endoscopic equipment development enabled to diagnose premalignant conditions and early gastric and colon cancer resulting in the rise of new methods of endoscopic treatment — endoscopic mucosal resection and endoscopic submucosal dissection. The advantages of such operation are obvious — minimal invasion, organ function preservation, a reduced hospitalization period, though these interventions carry the risk of iatrogenic complications (bleeding, perforation). Perforation is the most dangerous complication requiring immediate laparotomy.

The authors have described a case of successful application of endoscopic suturing device to manage gastric wall iatrogenic perforation resulted from endoscopic submucosal dissection for submucous gastric tumor. The defect was closed using Apollo Overstitch endoscopic suturing device (USA) avoiding laparotomy. The postoperative period was uneventful, and the patient was discharged 5 days after surgery.

Key words: endoscopic submucosal dissection; gastric wall perforation; endoscopic suturing device.

Recent advancements in endoscopic equipment enabled the diagnosis of precancerous diseases and early forms of gastric and colon cancer, which led to the emergence of new methods of endoscopic treatment — endoscopic resection of the mucous membrane and endoscopic dissection in the submucosal layer [1–4]. Though the advantages of endoscopic interventions are quite evident (minimal invasiveness, preserving organ functions, shortening of hospital staying), these methods have some weak points as well — the possibility of iatrogenic complications (hemorrhages, perforations) during these procedures. Such complications occur in 2–20% of patients [5–8]. Perforation is the most dangerous of them.

A standard treatment of perforations made during endoscopic operation is the transfer to laparotomy with the suture of the perforated hole [9–12].

A case of the first successful application of endoscopic suturing device in the Russian Federation for the management of iatrogenic perforation of the gastric wall is presented below.

A patient K., a 68-year-old woman, was admitted to oncological department No. 2 of affiliated clinic No.1 of Nizhny Novgorod Regional Oncological Dispensary with a diagnosis “submucous gastric tumor”. It was a planned hospitalization. Gastroscopy showed a 2.5 cm lesion, located on the anterior wall of the lower third of the stomach body. According to the endoscopic US findings the formation occupied mucosal and submucosal layers without invasion into the muscular layer of the gastric wall. Computed tomography (CT) and US examination of the abdominal cavity did not reveal any additional pathology. The decision was made to remove the tumor by endoscopic dissection in the submucosal layer. The operation was performed Nov. 28, 2013 under intubation anesthesia in the position of the patient lying on the left side. CO₂ was used for insufflation. A single channel gastroscope GIF-Q165 (Olympus, Japan) was introduced into the stomach, the margins of the formation were marked by electrocautery (Fig. 1). By means of endoscopic needle physiological solution with addition of indigocarmine was injected to the submucosal layer.

For contacts: Mitrakov Alexandr Anatolievich, phone +7 930-700-33-84; e-mail: alexandr_mit@mail.ru

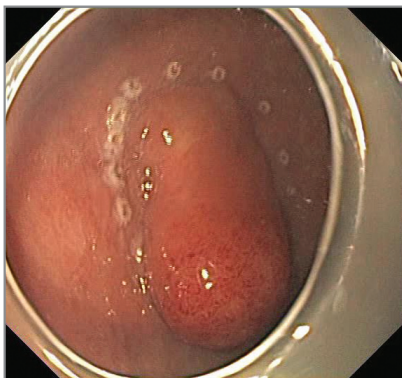


Fig. 1. The margins of the neoplasm on the anterior lower third of the stomach body are marked by electrocautery (white dots around the tumor)

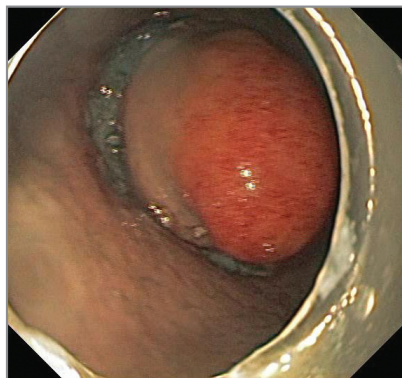


Fig. 2. Circular incision made around the neoplasm

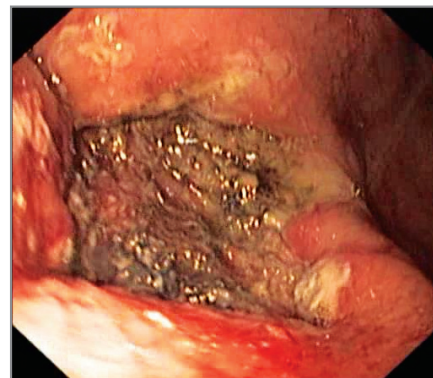


Fig. 3. Defect of mucosal and submucosal stomach wall layers after endoscopic elimination of the tumor en bloc

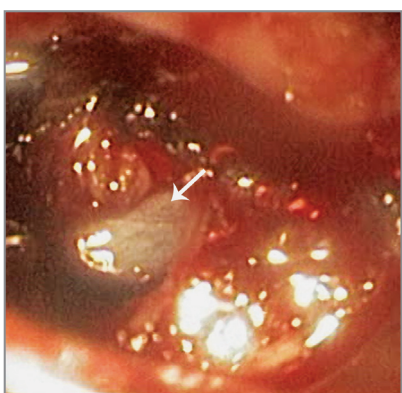


Fig. 4. A bowel loop inside the abdominal cavity (shown by a white arrow) is seen through the perforation hole

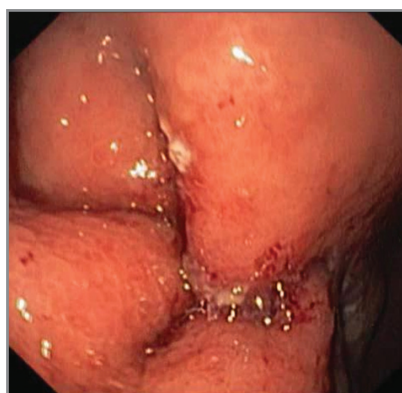


Fig. 5. The defect of the mucosal and submucosal gastric wall layers after tumor removal is completely closed by a continuous suture using endoscopic suturing device Overstitch

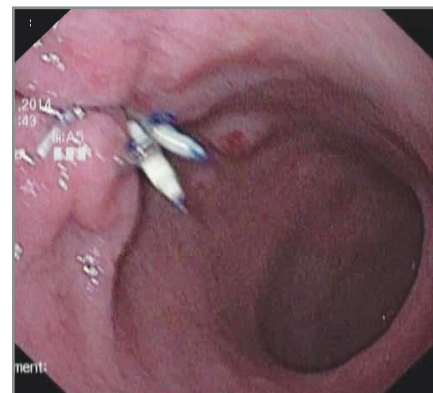


Fig. 6. Endoscopic control at day 6, demonstrating a complete defect closure following endoscopic resection by endoscopic sutures

At the first stage a circular incision around the tumor was made (Fig. 2), the tumor was removed en bloc within the healthy tissues using endoscopic dissection technique in the submucosal layer (Fig. 3) Dissection was complicated by excessive arterial bleeding from the vessel supplying the tumor. During vessel coagulation in the ForcedCoag mode by means of forceps RadialJaw (Boston Scientific, USA) perforation of the stomach wall occurred. The hole dimension was 5 mm, through which bowel loops in the abdominal cavity were clearly visualized (Fig. 4). A single-channel endoscope was replaced by a double-channel one (GIF-2T180, Olympus, Japan) with an endoscopic suturing device (Overstitch, Apollo EndoSurgery Inc., USA), mounted on the distal end of the endoscope. Successively guiding the needle of the suturing device through the opposite defect margins, two continuous sutures were made, each of which included four sticks by the needle on each side of the post-operative defect. Tightening and fixation of the sutures by the suturing device closed completely the gastric wall defect (Fig. 5). In the following insufflations of carbon dioxide full straightening of the stomach folds was

observed, which proved impermeability of endoscopic sutures. The endoscope was pulled out and nasogastral probe introduced.

The patient was administered a wide-spectrum antibiotic (Ampisid) in the dose 1.5 g intravenously 3 times a day for 3 days.

The day after the operation the patient felt satisfactory, peritoneal symptoms were absent, the plain radiograph showed no free air in the abdominal cavity. On the second post-operative day she began to eat, on the 6th day an endoscopic control was performed (Fig. 6) and on the 7th day she was discharged in the satisfactory condition.

Control endoscopic examination in 6 weeks after the intervention (Jan. 9, 2014) demonstrated complete healing of the endoscopic dissection area.

Minimal invasive intraluminal endoscopic operations are applied with growing frequency for removal mucosal and submucosal formations of the stomach, esophagus, large and small intestine. The heaviest and potentially fatal complication of such interventions

is iatrogenic perforation of the hollow organ wall. The process of closure of this defect with the help of endoclips is rather labor- and time-consuming, and not always successful [13–15], that is why nowadays a standard treatment in iatrogenic perforations in Russia and abroad is, as it always has been, the transfer to laparotomy or laparoscopy with a suture of the perforation [9–12].

A case of successful endoscopic suturing of iatrogenic perforation of the gastric wall using endoscopic suturing device Overstitch (Apollo EndoSurgery Inc., USA) is presented here. The perforation of the gastric wall, generated in the course of making endoscopic submucosal dissection, was hermetically closed by two continuous endoscopic sutures. Suturing of the defect took only 20 min and allowed to avoid the transfer to laparoscopic or open abdominal operation. The post-operative period was uneventful, endoscopic control showed a good healing of the gastric wall defect.

The obtained results of endoscopic treatment of the gastric wall perforation using endoscopic suturing device demonstrated the efficacy, technical simplicity, and reliability of this method.

References

1. Oyama T., Tomori A., Hotta K., et al. Endoscopic submucosal dissection of early esophageal cancer. *Clinical Gastroenterology Hepatology* 2005; 3(7 Suppl 1): S67–S70.
2. Gotoda T. A large endoscopic resection by endoscopic submucosal dissection procedure for early gastric cancer. *Clinical Gastroenterology Hepatology* 2005; 3(7 Suppl 1): S71–S73.
3. Yamamoto H. Endoscopic submucosal dissection for early cancers and large flat adenomas. *Clinical Gastroenterology Hepatology* 2005; 3(7 Suppl 1): S74–S76.
4. Yamamoto H., Yahagi N., Oyama T. Mucosectomy in the colon with endoscopic submucosal dissection. *Endoscopy* 2005; 37: 764–768.
5. Oda I., Suzuki H., Nonaka S., Yoshinaga S. Complications of gastric endoscopic submucosal dissection. *Digestive Endoscopy* 2013; 25(Suppl 1): 71–78, <http://www.dx.doi.org/10.1111/j.1443-1661.2012.01376.x>.
6. Oda I., Gotoda T., Hamanaka H., et al. Endoscopic submucosal dissection for early gastric cancer: technical feasibility, operation time and complications from a large consecutive series. *Digestive Endoscopy* 2005; 17: 54–58.
7. Chung I.K., Lee J.H., Lee S.H., et al. Therapeutic outcomes in 1000 cases of endoscopic submucosal dissection for early gastric neoplasms: Korean ESD Study Group multicenter study. *Gastrointestinal Endoscopy* 2009; 69(7): 1228–1235, <http://www.dx.doi.org/10.1016/j.gie.2008.09.027>.
8. Hanaoka N., Uedo N., Ishihara R., et al. Clinical features and outcomes of delayed perforation after endoscopic submucosal dissection for early gastric cancer. *Endoscopy* 2010; 42(12): 1112–1115, <http://www.dx.doi.org/10.1055/s-0030-1255932>.
9. Taku K., Sano Y., Fu K.I., Saito Y. Iatrogenic perforation at therapeutic colonoscopy: should the endoscopist attempt closure using endoclips or transfer immediately to surgery? *Endoscopy* 2006; 38(4): 428, <http://www.dx.doi.org/10.1055/s-2006-925248>.
10. Soroka A.K. Rational diagnosis and treatment options of perforated pyloroduodenal ulcer in young patients. *Endoskopicheskaya khirurgiya* 2013; 3: 3–7.
11. Krekoten' A.A., Agapov M.Yu., Barsukov A.S., Stegnyy K.V., Eliseyev M.S. Complications of endoscopic resection of gastrointestinal neoplasms and correction techniques. *Pacific Medical Journal* 2011; 4: 17–18.
12. Panteris V., Haringsma J., Kuipers E.J. Colonoscopy perforation rate, mechanisms and outcome: from diagnostic to therapeutic colonoscopy. *Endoscopy* 2009; 41(11): 941–951, <http://www.dx.doi.org/10.1055/s-0029-1215179>.
13. Shimizu Y., Kato M., Yamamoto J., et al. Endoscopic clip application for closure of esophageal perforations caused by EMR. *Gastrointestinal Endoscopy* 2004; 60(4): 636–639.
14. Tsunada S., Ogata S., Ohyama T., et al. Endoscopic closure of perforations caused by EMR in the stomach by application of metallic clips. *Gastrointestinal Endoscopy* 2003; 57(7): 948–951.
15. Sekiguchi M., Suzuki H., Oda I., et al. Dehiscence following successful endoscopic closure of gastric perforation during endoscopic submucosal dissection. *World J Gastroenterol* 2012 Aug 21; 18(31): 4224–4228, <http://www.dx.doi.org/10.3748/wjg.v18.i31.4224>.