

CAPABILITIES OF POSITRON EMISSION TOMOGRAPHY WITH ^{18}F -FLUORODEOXYGLUCOSE AND ^{11}C -METHIONINE IN DETERMINING PULMONARY TUBERCULOSIS ACTIVITY: METABOLIC AND MORPHOLOGICAL PARALLELS

UDC 616.24-002.5-073.756.8-021-091
Received 19.06.2014



M.S. Tlostanova, PhD, Nuclear Medicine Physician, Positron Emission Tomography Unit¹;
E.A. Popova, Surgeon, the Surgical Department of Combined and Complicated Forms of Pulmonary Tuberculosis²;
A.O. Avetisjan, PhD, Head of the Surgical Department of Combined and Complicated Forms of Pulmonary Tuberculosis²;
N.M. Bljum, Head of Pathomorphology Division²;
A.R. Kozak, PhD, Surgeon, the Surgical Department of Combined and Complicated Forms of Pulmonary Tuberculosis²;
A.M. Petrun'kin, PhD, Tutor, Hospital Surgery Department, the Medical Faculty³

¹Russian Research Center of Radiology and Surgical Technologies, Ministry of Healthcare of Russia, Leningradskaya St., 70, Pesochniy pos., Saint Petersburg, Russian Federation, 197758;

²Saint Petersburg Research Institute of Phthisiopulmonology, Ministry of Healthcare of Russia, Ligovsky Avenue, 2/4, Saint Petersburg, Russian Federation, 191036;

³Saint Petersburg State University, Universitetskaya naberezhnaya, 7-9, Saint Petersburg, Russian Federation, 199034

The aim of the investigation was to study the relationship between ^{18}F -fluorodeoxyglucose (^{18}F -FDG) and ^{11}C -methionine accumulation levels and the activity degree of inflammatory process in patients with pulmonary tuberculosis using positron emission tomography (PET).

Materials and Methods. We analyzed the findings of multi-spiral computed tomography, PET with ^{18}F -FDG and ^{11}C -methionine in 45 operated patients with tuberculosis. Chest PET was performed according to a standard protocol, 120 min after ^{18}F -FDG administration and 15 min after ^{11}C -methionine injection. The processing of PET findings included visual image analysis and calculations Standardized Uptake Value (SUV) in an intact lung and tuberculoma area. In addition to radiological methods we used luminescent microscopy of sputum smear, culture sputum, and polymerase chain reaction. Tuberculosis morphological activity was assessed according to B.M. Ariel classification.

Results. According to laboratory techniques, bacterial activity of tuberculosis was found in 25 patients (55.5%). PET with ^{18}F -FDG in all patients showed radiopharmaceutical hyperfixation focus in tuberculoma area that indicated the inflammatory process activity. In PET with ^{11}C -methionine, the accumulation of radiopharmaceuticals in tuberculoma area was revealed only in 27 patients (60%). SUV analysis showed accumulation levels in PET with both radiopharmaceuticals to increase in proportion to the growth of tuberculosis activity rate.

Conclusion. Accumulation levels of ^{18}F -FDG and, to a lesser degree, ^{11}C -methionine reflect morphological activity of tuberculosis. Since ^{11}C -methionine does not accumulate at all or accumulates in small amounts in I, II, III morphological activity tuberculomas, ^{11}C -methionine is preferable to use to differentiate pulmonary cancer and tuberculosis. The informativeness of laboratory techniques in post-therapy tuberculosis activity determination is low.

Key words: positron emission tomography; ^{18}F -FDG; ^{11}C -methionine; tuberculosis morphological activity.

Until recently, in many countries worldwide pulmonary tuberculosis is one of the most significant and socially important medical problems related to its high prevalence rate (mainly, among working age population), the problems of early diagnosis of an inflammatory process, as well as the growing number of newly diagnosed cases of multidrug resistant tuberculosis. Frequently, low chemosensitivity is found in patients with destructive tuberculosis forms: tuberculomas with cavities, as well as cavitary disease and fibro-cavernous tuberculosis. As a rule, lung cavitation is a crucial point in the course

of the disease, since there is high risk of brochogenic involvement. Early surgical techniques enable to improve considerably the disease outcome in these patients. Moreover, time and extent of the surgery directly depend on the inflammatory process activity usually assessed by the complex of clinical, radiological, laboratory findings and functional data. However, the combined use of these techniques enables to assess adequately the activity of tuberculosis process both in the lung and also in lymphatic basins not in all cases.

The present work for the first time has studied the

For contacts: Tlostanova Marina Sergeevna, e-mail: tlostanovamarina@gmail.com

feasibilities of positron emission tomography (PET) with ^{18}F -fluorodeoxyglucose (^{18}F -FDG) and ^{11}C -methionine to determine pulmonary tuberculosis activity by comparing morphological and metabolic data in patients with tuberculomas. The reasons that brought us about using ^{18}F -FDG and ^{11}C -methionine as tuberculosis activity markers were the reports of various authors about the property of the mentioned radiopharmaceuticals (RP) to accumulate not only in malignancies but also in inflammation foci [1–4]. In addition, many researchers indicate that the levels of ^{18}F -FDG and ^{11}C -methionine accumulation in inflammation areas depending on the disease etiology may vary between very wide limits [5]. In patients with local pneumofibrosis the uptake intensity of both RP, as a rule, slightly exceeds the level of their accumulation in intact pulmonary parenchyma. However, the accumulation indices of ^{18}F -FDG and, to a lesser extent, ^{11}C -methionine, in active tuberculosis patients are oftentimes in the same interval with uptake levels recorded in lung cancer patients. Maximum accumulation indices of both RP indistinguishable from those in patients with lung cancer are found in patients with lung abscess. Moreover, in patients with the same inflammatory disease accumulation levels of both ^{18}F -FDG and ^{11}C -methionine can also differ significantly [5, 6].

Based on the above mentioned, we supposed that a wide range of both RP uptake levels registered in the inflammation foci depends not only on etiology, but also reflects the degree of the disease activity. According to our reckoning, the study of the relationship between these criteria will enable to apply PET as the secondary non-invasive technique to determine the inflammatory process activity, as well as help deal with the causes of false-positive results sometimes obtained when using a differential diagnostic method for lung cancer and some non-neoplastic lung diseases, e.g., tuberculosis.

The aim of the investigation was to study the relationship between ^{18}F -fluorodeoxyglucose and ^{11}C -methionine accumulation levels and the activity degree of inflammatory process in patients with pulmonary tuberculosis using positron emission tomography.

Materials and Methods. For the purpose of the study we analyzed retrospectively the findings of multi-spiral computed tomography (MSCT), as well as PET with ^{18}F -FDG and ^{11}C -methionine in 45 patients after radical surgery for tuberculoma aged from 26 to 60 years. All patients before surgery received anti-tuberculosis drug therapy within 12.4 ± 2.6 months.

The present retrospective study was approved by the Ethics Committee of Russian Research Centre for Radiology and Surgical Technologies, Ministry of Healthcare of Russia and complies with the Declaration of Helsinki (adopted in June, 1964 (Helsinki, Finland) and revised in October, 2000 (Edinburg, Scotland)). Written informed consent was obtained from all patients.

PET was performed according to a standard protocol

consisting in sequential chest scanning 120 min after ^{18}F -FDG administration, and 15 min after ^{11}C -methionine injection. The study with ^{18}F -FDG and ^{11}C -methionine was carried out in different days. So, ^{11}C -methionine-PET was performed on the following day after ^{18}F -FDG-PET. The processing of data regardless of RP used included a visual study of tomoscintigrams in order to reveal the areas of high RP accumulation in tuberculoma, and the calculation of maximum standardized uptake value (SUV). SUV was calculated automatically taking into consideration the indices of physical half-life of the used radionuclide by the formula:

$$SUV = \frac{RP \text{ radioactivity concentration in the range of interest (MBq/g)}}{\text{administered activity of RP (MBq)/body}}$$

Apart from MSCT, PET with ^{18}F -FDG and ^{11}C -methionine all patients underwent complex laboratory examination. To assess a patient's capability to bacterioexcretion, we performed luminescent microscopy of sputum smear prepared using fluorochrome dyes — 0.1% auramine O and 0.01% rhodamine C. In addition, in all patients we studied culture sputum using Lowenstein–Jensen and Finn-II solid media, as well as computer-assisted system BACTEC MGIT 960 (BD, USA). The findings were assessed on the average 2–3 weeks after culture. Moreover, to isolate acid-fast microbacterium and determine its type in all cases we used polymerase chain reaction (PCR), which enables to reveal amplified nucleotide sequences IS6110 tracing Mycobacterium tuberculosis complex. PCR findings were assessed on an analyzer iCycler iQ 5 (BioRad, USA) in real-time mode.

After radiological and clinical laboratory examination all patients with tuberculomas underwent radical organ preserving surgeries: segmental and lobar resections combined with regional lymph node dissection. After a detailed study of a removed macroscopic specimen it was fixed in 10% neutral formaline. Further, the preparations were hematoxylin-eosin, and van Gieson and Ziehl–Nielsen stained.

The activity of tuberculosis process was assessed using B.M. Ariel classification [7] indicating the relationship between caseous necrotic masses and fibrous changes revealed in the tuberculoma and adjacent pulmonary tissue. Simultaneously we determined the stage of bronchi and regional lymph nodes involvement in an inflammatory process. According to the mentioned classification, 5 tuberculosis activity degrees were distinguished: subsiding inflammatory process was referred to activity degree I, limited active tuberculosis — II degree, stable inflammatory process — III degree, inflammatory changes with the progression starting — IV degree, acute progressive tuberculosis — V degree. The patients were grouped based on this classification.

PET findings were statistically processed using parametric and nonparametric statistics. Descriptive statistical methods included estimated arithmetic mean

(M) and estimated mean error (m). Critical confidence level of null statistic hypothesis was considered equal 0.05.

Results. According to laboratory findings bacterial activity of tuberculosis was found in 25 (55.5%) of 45 examined patients with lung tuberculomas: in one patient — according to luminescent microscopy of sputum smear, in 7 — by culture sputum assessment, in 17 — by PCR.

Chest MSCT in all patients with tuberculomas showed a single mass in pulmonary parenchyma. Radiological pattern of the mass, as well as the surrounding pulmonary parenchyma depended on tuberculoma stage. The sizes of the found masses varied from 1.0 to 5.6 cm and averaged to 1.97 ± 0.22 cm. Most frequently, 26 out of 45 patients (57.8%) had subpleural tuberculomas located in different segments of the right upper lung.

^{18}F -FDG-PET revealed RP hyperfixation focus in tuberculoma area in all examined patients (n=45) that indicated the activity of an inflammatory process. Maximum SUV levels in the revealed foci varied from 0.88 to 10.3 and averaged 2.85 ± 0.35 , SUV in intact pulmonary parenchyma being 0.60 ± 0.05 .

^{11}C -methionine-PET showed RP accumulation in tuberculoma area in 27 out of 45 examined patients (60%), and maximum SUV levels in the revealed foci varied from 1.0 to 5.0, and averaged 2.03 ± 0.17 . The rest patients (n=18, 40%) with tuberculomas were found

to have background RP accumulation corresponding to normal pulmonary parenchyma. SUV in intact pulmonary parenchyma was 1.0 ± 0.02 .

The distribution analysis of SUV calculated for ^{18}F -FDG-PET and ^{11}C -methionine-PET in tuberculoma area depending on the inflammatory process activity (See the Table) showed that SUV increased as far as the tuberculosis activity grew, when both RP were used. ^{18}F -FDG-PET demonstrated significant differences between SUV levels in group 1 and 2 patients ($p=0.0044$), as well as group 3 and 4 patients ($p=0.0286$). ^{11}C -methionine-PET showed similar results. In patients with inflammatory process remission in the lung SUV were significantly lower than in patients with II degree of activity ($p=0.0121$). In groups with III and IV degrees of activity SUV indices also differed significantly ($p=0.0055$). On the other hand, SUV values did not significantly differ at both ^{18}F -FDG-PET and ^{11}C -methionine-PET in patients with II and III, as well as with IV and V degrees of tuberculosis activity ($p \leq 0.05$). It should be noted that in PET with both RP in patients with the remission of the inflammatory process SUV levels in tuberculoma area did not significantly differ from those recorded in intact pulmonary parenchyma. However, the patients with progressive tuberculosis (IV and V degrees) had the highest SUV both in ^{18}F -FDG-PET and ^{11}C -methionine-PET.

Fig. 1, 2 present the findings of MSCT, ^{18}F -FDG-PET and ^{11}C -methionine-PET in a 49-year-old patient K. with

Distribution of SUV indices calculated at ^{18}F -FDG-PET and ^{11}C -methionine-PET in tuberculoma area depending on the inflammatory process activity degree (M±m)

Tuberculosis activity degree	SUV levels in ^{18}F -FDG-PET	SUV levels in ^{11}C -methionine-PET
I degree — subsiding inflammatory process (n=7)	0.88 ± 0.15 (from 0.8 to 1.8)	1.01 ± 0.01 (from 1.0 to 1.1)
II degree — limited active tuberculosis (n=11)	2.38 ± 0.60 (from 0.9 to 5.8)	1.26 ± 0.13 (from 1.0 to 1.8)
III degree — stable inflammatory process (n=15)	2.70 ± 0.29 (from 1.2 to 5.3)	1.31 ± 0.09 (from 1.0 to 2.2)
IV degree — inflammatory changes with the progression starting (n=7)	4.07 ± 0.66 (from 2.24 to 6.1)	2.30 ± 0.27 (from 1.3 to 2.9)
V degree — acute progressive tuberculosis (n=5)	7.45 ± 2.85 (from 4.6 to 10.3)	3.45 ± 1.55 (from 1.9 to 5.0)

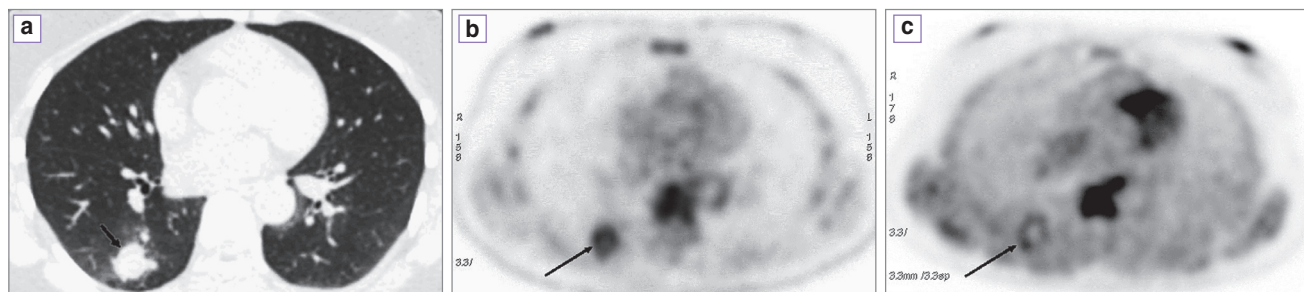
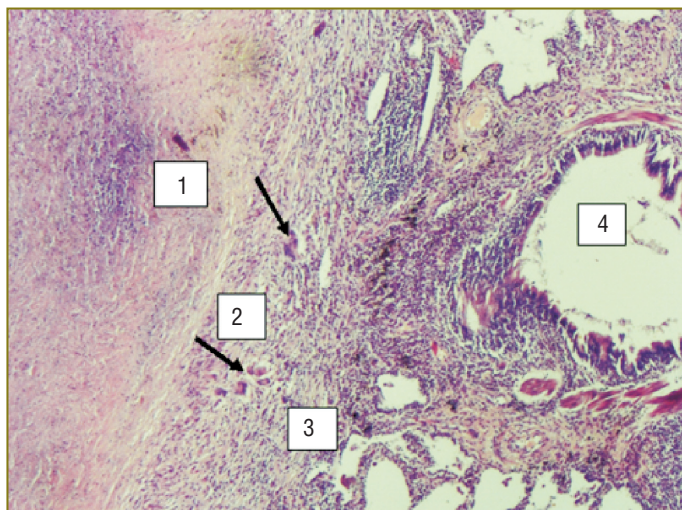


Fig. 1. MSCT (a) of S6 segment of the right lung shows a rounded dense mass (arrow), $1.9 \times 2.1 \times 1.9$ cm in size, with heterogeneous structure due to the calcification of peripheral parts. Around the mass there are the signs of increased pulmonary vascularity mainly due to the interstitial process. ^{18}F -FDG-PET (b), the view of the mass, in segment S6 of the right lung shows the ring-shaped lesion of pathological RP hyperfixation (arrow) (in the centre there is ametabolic zone), SUV=3.3. ^{11}C -methionine-PET (c), the view of the mass, in segment S6 of the right lung shows the ring-shaped lesion of pathological RP hyperfixation (arrow) (in the centre there is ametabolic zone), SUV=1.6

Fig. 2. A fragment of caseous necrotic lesion in a female patient with III activity degree tuberculoma. Caseous masses (1) are friable, contain detritus, and have partial parietal, irregularly marked structural arrangement. Caseous masses are surrounded by a two-layered capsule: an inner layer consisting of epithelioid cells (2) with single multinucleated giant cells (arrows), an outer layer is a formed fibrous capsule (3) with persisting lymphoplasmocytic infiltration. A small-sized bronchus (4) with chronic catarrhal inflammation is closely adjacent to the lesion wall



the right lower tuberculoma, the morphological data being illustrated.

Discussion. Pulmonary tuberculosis treatment regardless its clinical form is well known to be a long, time-consuming process, and unfortunately, it does not always result in complete recovery. Generally, the therapy of newly diagnosed pulmonary tuberculosis is conservative including tuberculostatic chemotherapy against a strict hygienic and dietary regimen. However, in case of medical therapy failure, as a rule, a combination therapy is used including surgery. The decision of surgery, its character, time and volume directly depend on the extension and activity of tuberculosis process. Tuberculoma is one of clinical forms of secondary tuberculosis, and lung resection following the conservative treatment is actually the only chance for a patient to avoid the disease progression. However, to make a decision of the necessary operative therapy one should have a true representation of the tuberculosis process activity. Frequently, in patients with tuberculomas, it is a challenging task, especially if an X-ray pattern is stable and there are no laboratory signs of bacterioexcretion. Meanwhile, the decision if the surgery is reasonable should be made as early as within the first 6 months after conservative treatment initiation, which usually appears to be ineffective in patients with tuberculomas. Conservative treatment failure is due to a fibrous capsule of tuberculoma, the capsule being almost impermeable for chemotherapeutic agents.

The findings of the present study have clearly demonstrated the difficulties, which appear when estimating the activity of tuberculosis process after conservative treatment by determining the presence or absence of bacterioexcretion in patients with tuberculomas. According to our findings, after bacterioscopy of sputum smear, the estimation of culture sputum, and PCR, bacterial activity of tuberculosis was found only in 25 patients (55.5%). Bacterioexcretion in all patients clearly indicated the failure of medical therapy

and was a direct surgical indication. However, as for the rest patients is concerned, who had no laboratory data for bacterioexcretion ability, their surgical indications should be considered as relative, and these patients should be referred to as a group of clinically treated patients. Instead, according to histological findings, all these patients retained morphological signs of the disease activity.

The study of the findings of ^{18}F -FDG-PET following the medical therapy showed the activity of tuberculosis process to be recorded in all cases that completely agree with histological findings. So, ^{18}F -FDG-PET in all examined patients regardless their ability to bacterioexcretion revealed in tuberculoma area an increased ^{18}F -FDG uptake that indicated persisting activity of tuberculosis process in spite of the treatment provided.

^{11}C -methionine-PET findings appeared to be less conclusive, and were consistent with the laboratory data. So, ^{11}C -methionine-PET showed RP hyperfixation in tuberculoma, which means the activity of a specific process, the hyperfixation being recorded in 27 patients only (60%). Moreover, the patients of the main group with tuberculomas accumulated ^{11}C -methionine were those with nascent progression of tuberculosis and acute progressive tuberculosis (IV and V degrees of activity). RP SUV levels of the patients despite the persisting tuberculosis activity were low, or did not differ at all from the indices recorded in intact pulmonary parenchyma. Morphological characteristics of tuberculomas in these patients corresponded to remission, local active or stable tuberculosis, i.e. referred to I, II and III degrees of tuberculosis activity.

Thus, the obtained results enabled to conclude that it is reasonable to perform ^{18}F -FDG-PET to determine the tuberculosis process activity, especially in patients with ambiguous, mainly laboratory, data on their response to the treatment provided. It is ^{18}F -FDG-PET, which results coincided with the morphological data of tuberculomas. The use of ^{11}C -methionine made it possible to confirm

the activity of an inflammatory process in 60% patients only. However, PET appeared to be unnecessary, since the same was revealed by laboratory diagnostics. In this regard, we concluded it is unreasonable to use ^{11}C -methionine to determine the activity of tuberculosis process.

It should be noted that when analyzing the findings, we aimed at studying the capabilities of PET to determine the lung tuberculosis activity. Meanwhile, in most researches concerned with the use of PET in patients with respiratory pathology, the technique is used to solve quite different problems, related primarily to differential diagnosis of lung cancer and inflammatory diseases. In addition, the overwhelming majority of foreign and Russian researchers report that the accuracy of ^{18}F -FDG-PET in differentiating malignant and inflammatory lesions in the lungs is low due to an increased RP uptake in the inflammation area [1, 3]. A few authors report on similar problems of false-positive results of ^{11}C -methionine-PET [2, 4]. However, the findings of a comparative study of the informativeness of ^{18}F -FDG-PET and ^{11}C -methionine-PET in differentiation of tumor and inflammatory pulmonary diseases we previously published indicate ^{11}C -methionine to be more effective [5, 6]. According to these findings, the sensitivity of ^{11}C -methionine-PET and ^{18}F -FDG-PET in differentiating lung cancer and inflammatory diseases was 89.5 and 91.8%, specificity — 82.8 and 52.2%, diagnostic accuracy — 86.9 and 79.5%, respectively.

From our point of view, the peculiarities of ^{18}F -FDG and ^{11}C -methionine distribution in tuberculomas depending on their morphological activity revealed in the present study enable not only to estimate the role and the position of the technique in tuberculosis activity assessment, but also explain significant differences in PET informativeness when using RP to solve the problems dealing with lung cancer and tuberculosis differentiation. According to our reckoning, the main cause of lower information value of ^{18}F -FDG-PET in differential diagnostics of lung masses is ^{18}F -FDG ability to accumulate in inflammatory foci in tuberculosis forms of any morphological activity including I and II activity degrees. In turn, it results in many false-negative results obtained by ^{18}F -FDG-PET. In addition, the ability of ^{11}C -methionine to accumulate only in inflammatory foci characterized by high (IV and V) activity degrees enables to assess the character of a lung lesion more accurately. In this regard, we came to the conclusion that it is preferable to use ^{11}C -methionine to differentiate tumor and inflammatory lung (primarily, tuberculosis) diseases.

Conclusion. The informativeness of laboratory techniques to determine post-therapeutic activity of an inflammatory process in patients with tuberculomas is low. ^{18}F -FDG-PET helps determine tuberculoma activity, especially in patients with ambiguous laboratory data on the response to treatment. It is unreasonable to use ^{11}C -methionine to solve these problems.

^{18}F -FDG accumulation levels directly depend on the morphological activity of tuberculosis. Increased ^{11}C -methionine accumulation in tuberculoma area is found only if the morphological activity of the disease is high. ^{11}C -methionine is preferable to use for differential diagnosis of lung cancer and active tuberculosis.

Study Funding and Conflict of Interests. The study was not funded by any sources, and there are no conflicts of interest related to the present study.

References

1. Kumar R., Halanaik D., Malhotra A. Clinical applications of positron emission tomography — computed tomography in oncology. *Indian J Cancer* 2010; 47(2): 100–119, <http://dx.doi.org/10.4103/0019-509X.62997>.
2. Hsieh H.J., Lin S.H., Lin K.H., Lee C.Y., Chang C.P., Wang S.J. The feasibility of ^{11}C -methionine-PET in diagnosis of solitary lung nodules/masses when compared with ^{18}F -FDG-PET. *Ann Nucl Med* 2008; 22(6): 533–538, <http://dx.doi.org/10.1007/s12149-007-0142-8>.
3. Wang T., Sun Y., Chu X., Yao S.L., Yang B., Tian J.H., et al. Positron emission tomography with special tracers in pulmonary abnormalities. *Zhonghua Wai Ke Za Zhi* 2010; 48(2): 99–102.
4. Zhao S., Kuge Y., Kohanawa M., Takahashi T., Zhao Y., Yi M., et al. Usefulness of ^{11}C -methionine for differentiating tumors from granulomas in experimental rat models: a comparison with ^{18}F -FDG and ^{18}F -FLT. *J Nucl Med* 2008; 49(6): 135–141, <http://dx.doi.org/10.2967/jnumed.107.044578>.
5. Tlostanova M.S., Avetisyan A.O. The informativeness of positron emission tomography with [^{18}F]fluorodeoxyglucose in differential diagnosis of lung cancer. *Vestnik RGMU* 2012; 2: 41–44.
6. Tlostanova M.S., Avetisjan A.O., Kozak A.R., Pishhik V.G. Clinical experience of utilization of positron emission tomography with ^{11}C -methionine in patients with newly diagnosed lung tumors. *Radiologiya — praktika* 2014; 2: 26–36.
7. Ariel' B.M., Bellinder E.N. Patologicheskaya anatomiya i patogenez tuberkuleza. V kn.: *Rukovodstvo po legochnomu i vnelegochnomu tuberkulezu* [Pathological anatomy and pathogenesis of tuberculosis. In: Guidelines on pulmonary and extrapulmonary tuberculosis]. Nauch. red. Levashev Yu.N., Repin Yu.M. [Levashev Yu.N., Repin Yu.M. (editors)]. Saint Peterburg: ELBI-SPb; 2006; p. 67–94.