

SUPERIOR MESENTERIC VEIN ISOLATION TECHNIQUE IN PROXIMAL PANCREAS RESECTION

UDC 616.37–089.87+616.143–089.88
Received 5.05.2014



G.M. Barvanyan, PhD, Head of the Surgery Department

Komi Republican Hospital, Pushkin St., 114/2, Syktyvkar, Komi Republic, Russian Federation, 67004

The aim of investigation was to develop superior mesenteric vein (SMV) isolation technique in proximal pancreas resection, and assess possible ways of its application.

Materials and Methods. The characteristic of SMV isolation technique in proximal pancreas resection is primary isolation of the vein in the infra-colic space. In the treatment group (n=13) we used the suggested method of SMV isolation, in the comparison group (n=14) SMV was searched and isolated just near the inferior border of pancreas. We calculated the time required for SMV search and isolation to the inferior border of pancreas, and investigated hemostasis peculiarities.

Results. The treatment group patients required less time for SMV search and isolation than those of the comparison group — 16.8 ± 0.7 versus 21.2 ± 1.7 min; the difference being significant, $p=0.029$. Five cases of the comparison group were found to have a diffuse bleeding, and hemostasis appeared to be more time-consuming. Well-defined landmarks — the right border of mesentery and ileocolic vessels — help SMV search in infra-colic space.

Conclusion. The technique can be successfully used in dense network of enlarged venous vessels under the inferior border of pancreas, and in overweight patients with massive cellular tissue in SMV search and isolation area. The method can be of help for surgeons with brief experience of proximal pancreas resection.

Key words: superior mesenteric vein; proximal pancreas resection; isolation of superior mesenteric vein.

Proximal pancreas resection is currently widely used in tumors of the head of pancreas and chronic capitate pancreatitis. The isolation of the superior mesenteric vein (SMV) is one of the key points for pancreas proximal resection [1–3]. The identification and further isolation of SMV is often associated with the risk of injury to the minor arterial and venous vessels of the parapancreatic cellular tissue that causes diffuse bleeding and prolongs the operation time due to the need for hemostasis. This operation stage is rather time-consuming in patients with indurative inflammation or fibrosis of parapancreatic cellular tissue in overweight patients [4, 5]. The technical aspects of this stage of proximal pancreas resection are noted to be described only in the context of the technology of performing the operation.

The aim of the investigation was to develop a superior mesenteric vein (SMV) isolation technique in proximal pancreas resection, and to assess possible ways of its application.

Materials and Methods. In order to optimize the proximal pancreas resection technology we have designed and put into practice a new SMV isolation technique (Russian Federation patent for the invention No.2521353 from 30.04.2014). The technique is as follows. At a certain stage of the operation the omental bursa is opened. The transverse colon is turned upward,

and SMV is isolated below the mesentery of the transverse colon in a typical place at the right border of the mesentery root of the small intestine (Fig. 1). Tunnelization of the cellular tissue, which, as a rule, is loose and contains almost no blood vessels in this area, is performed above the anterior wall of the vein with the dissector or forefinger. The tool or finger of the surgeon remains in the the formed space above SMV. The tool or finger of the surgeon is identified on palpation in the omental bursa at the mesentery origin of the transverse colon, and the peritoneum is dissected in the avascular zone. A tourniquet is introduced into the formed tunnel above the superior mesenteric vein (Fig. 2). Then the transverse colon is turned downward. The area of the anterior wall of SMV at the mesentery origin of the transverse colon in the omental bursa becomes visible then (Fig. 3). Next, tissue dissection above SMV in the direction from the mesentery origin of the transverse colon to the pancreas is performed. Under constant visual control of the anterior wall of the vein, the SMV stem is isolated up to the inferior border of the pancreas.

The introduced technique of SMV isolation was used in 16 patients from 2007 to 2013. It was indicated to 13 patients with parapancreatic cellular tissue involvement in the pathological process. Indurative edema and marked infiltrative commissures in the parapancreatic cellular

For contacts: Barvanyan Georgiy Michailovich, e-mail: bgmee@yandex.ru

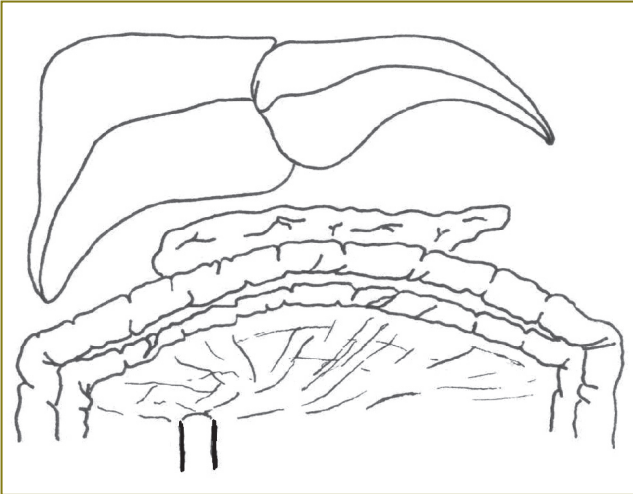


Fig. 1. Superior mesenteric vein is isolated in the infra colic space

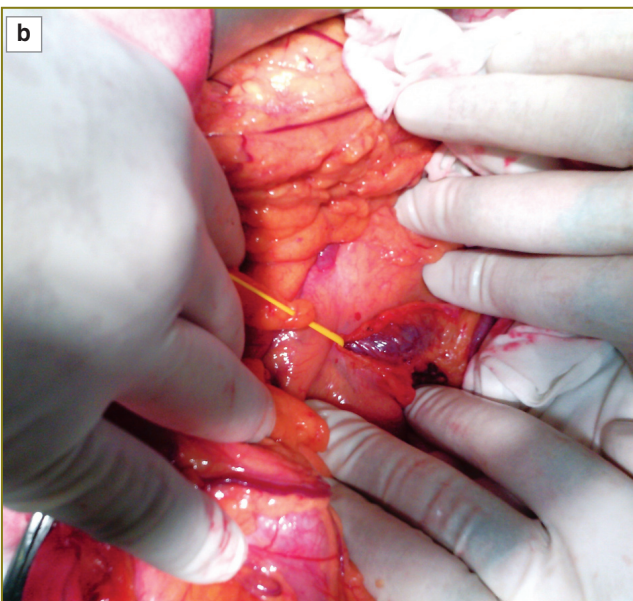
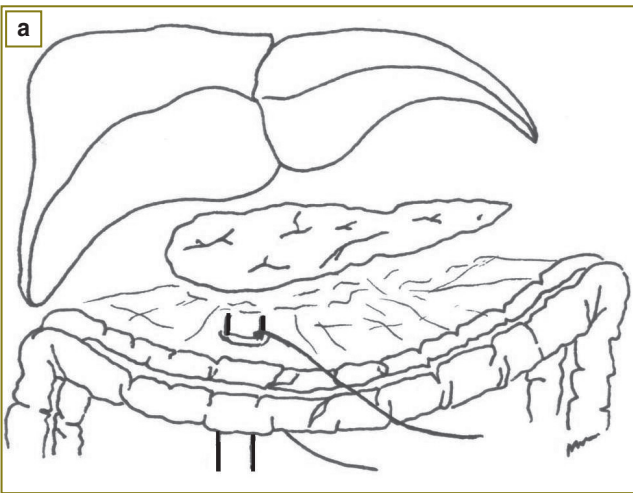


Fig. 2. A tourniquet is inserted above the superior mesenteric vein: a — diagram; b — photo

tissue are believed to be a pathological process that complicates SMV search and isolation. Due to technical difficulties in searching the vein in the cellular tissue below the inferior border of the pancreas, this method was also used in 2 patients with the body mass index of 42.3 and 46.6 and one patient with a dense vasculature around the pancreas (a portal hypertension feature). In 4 patients the initial attempt to isolate SMV directly at the inferior border of the pancreas was abandoned due to technical difficulties: diffuse bleeding (2 patients), inability to identify the vein in the cellular tissue (2 patients with IV degree obesity). Pancreatoduodenal resection was performed in 12 patients. In one case SMV was isolated before confluence, and the splenic vein was also isolated and legated 1 cm away from the portal vein when performing distal splenorenal venous shunt. In 3 cases at the stage of SMV isolation in the inferiocolic space we detected inability to perform radical surgery because of the super mesenteric vessels involvement in tumor conglomerate, and further vein isolation was stopped.

There were no intraoperative complications related to the suggested SMV method.

To assess the efficiency of the new technique of SMV isolation we performed a comparative analysis in two groups. The treatment group consisted of 13 patients, SMV isolation was performed with the introduced technique before the inferior border of the pancreas and its transition to the portal vein. The comparison group consisted of 14 patients in whom SMV search and isolation was performed directly at the inferior border of the pancreas. Difficulties in SMV isolation in 13 patients of the comparison group were associated with the search of the vein in the parapancreatic cellular tissue involved in the pathological process, and in one case — with dense

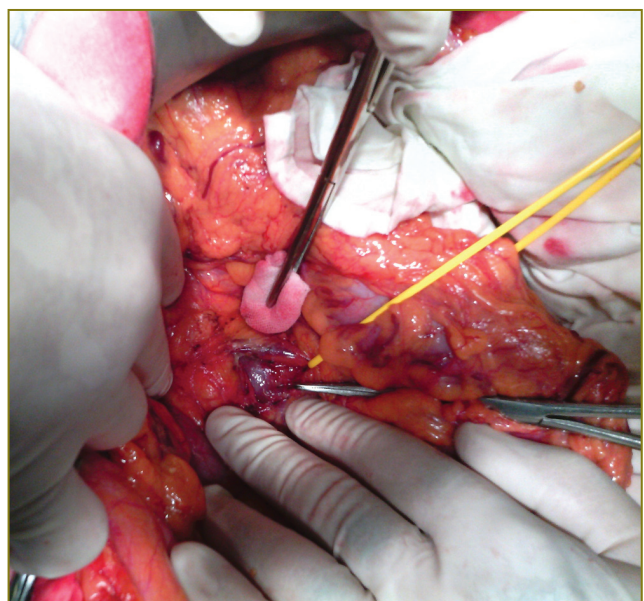


Fig. 3. Isolation of the superior mesenteric vein below the inferior border of the pancreas

vasculature in the pancreas projection. All the patients were treated in the Komi Republican Hospital in Syktyvkar. The study was carried out in accordance with the Helsinki Declaration (adopted in June, 1964 (Helsinki, Finland) and revised in October 2000 (Edinburgh, Scotland)). Informed consent was received from each patient.

Hemostasis and cellular tissue dissection at SMV isolation in both the groups were performed with the use of the Harmonic ultrasonic scalpel (Germany), the LigaSure electrosurgical complex (USA) and monopolar coagulation. Chronometry of the time spent on SMV search and isolation before the inferior border of the pancreas was conducted and the hemostasis peculiarities were investigated. The time spent on initial SMV search under the inferior border of the pancreas was not included in chronometry in 4 patients in the main group.

To analyze the statistical significance of the differences between the groups, we used the Mann–Whitney test. Statistically significant differences were considered to be at the significance level (p) of less than 0.05.

Results. The both studied groups were comparable in terms of clinical features (See the Table).

In the main group the following time values of SMV isolation were obtained (minutes): 15, 12, 14, 17, 15, 16, 18, 16, 19, 18, 19, 17, 22, on average 16.8±0.7. In the comparison group: 18, 15, 19, 31, 20, 17, 18, 13, 27, 21, 18, 19, 37, 24, on average 21.2±1.7 (p=0.029).

Tearing-off of the lateral vein tributary followed by bleeding occurred at the inferior border of the pancreas in one case in the main group. SMV was practically isolated and well visualized by that time. Suturing of the wall of the vein did not present any technical difficulties. Capillary bleeding was easily controlled by monopolar coagulation at cellular tissue dissection in the infra colic space and searching SMV. In the comparison group in three cases the separation of the lateral SMV tributaries during its isolation occurred. Due to the lack of visualization of the veins we had to re-suture the vascular wall in two cases. When searching and isolating SMV, in the comparison group there were 5 cases with diffuse bleeding in the cellular tissue in the area of operation, which impeded the surgeon's manipulations.

Massive hemorrhage was not observed during SMV search and isolation in any group. Tearing off of the lateral vein tributaries went with blood loss of approximately 50

to 100 ml. Blood loss estimation by weighing swabs was not performed due to the complexity and inaccuracy of the procedure.

Discussion. SMV and portal vein identification and isolation are the key point in proximal pancreas resection.

Various techniques of their isolation at proximal pancreas resection exist, though most surgeons prefer to perform it in the area between the inferior border of the pancreas and the mesentery root of the transverse colon [3, 4, 6, 7]. When the surrounding pancreas cellular tissue involved in the pathological process, SMV identification is technically difficult. First of all, it is connected with indurative cellular tissue inflammation that may develop with pancreas tumors and dense inflammatory process in chronic pancreatitis. According to the proposed technique, manipulations for SMV identification are performed in the infra colic space. SMV is isolated by clear landmarks: the right border of the mesentery of the small intestine and iliac-colic vessels. Under the mesentery root of the transverse colon the cellular tissue is almost never involved in indurative or fibrotic process of pancreatic etiology. The absence of small tributaries on the anterior wall of the vein allows performing a bloodless tunnelization of the cellular tissue at the mesentery root of the transverse colon and proceed with manipulations in the omental bursa. Further isolation up to the the inferior border of the pancreas is under constant visual control of its anterior wall.

The treatment group patients required less time for SMV search and isolation than those of the comparison group, the statistical difference being significant.

In the comparison group in 5 cases with diffuse bleeding, performing hemostasis at SMV isolation was more labour-consuming.

Conclusion. The proposed technique for superior mesenteric vein identification and isolation at the proximal resection of the pancreas with the involvement of the pancreas surrounding cellular tissue in the pathological process can reduce the time spent on this stage of the operation. This decreases the probability of injuring the vein. This technique may be applied in patients with a dense network of enlarged veins below the inferior border of the pancreas and in overweight patients with massive cellular tissue in the area of search and isolation of the superior mesenteric vein.

Research Funding and Conflict of Interest. The study was not funded by any sources, and the author declares to have no conflict of interest related to this study.

References

1. Kubyshkin V.A., Vishnevskiy V.A. *Rak podzheludochnoy zhelezy* [Pancreatic cancer]. Moscow: Medpraktika; 2003; 386 p.
2. Patyutko Yu.I., Kotel'nikov A.G. *Khirurgiya raka organov biliopankreatoduodena'noy zony* [Surgery of

Patients' clinical features

Features	Main group (n=13)	Comparison group (n=14)
Age, years	54.3±2.7 (from 42 to 75)	53.9±2.8 (from 39 to 71)
Sex, female/male	3/10	3/11
Tumor of periampular zone	10	11
Chronic pancreatitis	2	3
Distal splenorenal shunt	1	—

biliopancreatoduodenal cancer]. Moscow: Meditsina; 2007; 448 p.

3. Khanevich M.D., Manikhas G.M. *Kriokhirurgiya raka podzheludchnoy zhelezy* [Cryosurgery for pancreatic cancer]. Saint Petersburg: Agraf; 2011; 228 p.

4. Rogal' M.L., Koro-chanskaya N.V., Murashko N.V. Standards of pre-operative diagnostics in patients with complicated chronic pancreatitis. *Vestnik munitsipal'nogo zdravookhraneniya* 2010; 7(1). URL: <http://vestnik.kmldo.ru/pdf/10/01/10.pdf> (submission date: 19.05.2012).

5. Ramia J.M. Tricks and tips in pancreatoduodenectomy. *World J Gastrointest Oncol* 2014; 6(9): 344–350, <http://dx.doi.org/10.4251/wjgo.v6.i9.344>.

6. Dumitrascu T., David L., Popescu I. Posterior versus standard approach in pancreatoduodenectomy: a case-match study. *Langenbecks Arch Surg* 2010; 395(6): 677–684, <http://dx.doi.org/10.1007/s00423-009-0499-3>.

7. Xu Y.F., Liu Z.J., Gong J.P. Pancreaticoduodenectomy with early superior mesenteric artery dissection. *Hepatobiliary Pancreat Dis Int* 2010; 9(6): 579–583.