

THE USE OF SELECTIVE PHOTOTHERMOLYSIS WITH SCLEROSING TO TREAT CONGENITAL AND NEONATAL VASCULAR MAXILLOFACIAL HYPERPLASIA IN CHILDREN

UDC 616.5–007.61–022–053.1:615.8
Received 22.05.2014



D.V. Ryzhevskiy, Maxillofacial Surgeon, Plastic Surgeon, Head of the Third Laser Surgery Department¹;
V.V. Trubin, PhD, Associate Professor, Head of the Department of Surgical Dentistry and Maxillofacial Surgery²;
E.A. Durnovo, D.Med.Sc., Professor, Head of the Department of Surgical Dentistry and Maxillofacial Surgery³

¹The Academician S.N. Fyodorov Intersectoral Research and Technology Complex “Eye Microsurgery”, Ministry of Health of the Russian Federation, Cheboksary branch, Traktostroiteley pr., 10, Cheboksary, Russian Federation, 428028;

²Chuvash State University, Moskovsky pr., 15, Cheboksary, Russian Federation, 428015;

³Nizhny Novgorod State Medical Academy, Minin and Pozharsky Square, 10/1, Nizhny Novgorod, Russian Federation, 603005

The aim of the investigation was to assess the treatment efficacy of maxillofacial infantile hemangiomas by a single-stage use of selective photothermolysis and sclerosing compared to the isolated use of selective photothermolysis and conventional cryodestruction.

Materials and Methods. 250 clinical cases were studied. The patients were divided into three groups: group 1 — with cryodestruction (n=79), group 2 — selective photothermolysis (n=87), group 3 — combined treatment of selective photothermolysis and sclerosing (n=84). For the avoidance of doubt, we selected only similar clinical cases, the main selection parameter being the height and (or) depth of vascular hyperplasia invasion in intact tissues (from 5 to 9 mm), the involvement area being of secondary importance. The treatment efficacy criteria were the following: 1) reduction of the involvement area (cosmetic result) in the course of the first procedure; 2) the number of follow-ups of a growing tumor in a group per year; 3) reduction of treatment duration.

Results. Mean treatment time in combination of selective photothermolysis and sclerosing reduced by 60% compared to cryodestruction, and by 37% — compared to monotherapy (selective photothermolysis). Positive cosmetic result after the first treatment procedure exceeded that of monotherapies: cryodestruction — by 25.61%, and selective photothermolysis — by 14.77%. There was observed the reduced number of repeated procedures necessary for maximum tumor regress.

Conclusion. A combined technique of selective photothermolysis and sclerosing enables to improve the treatment efficacy of pediatric hemangiomas, improve functional and esthetic results, and reduce the time required for the management of children with this pathology.

Key words: hemangioma; fraction photothermolysis; vascular skin hyperplasia.

Vascular hyperplasias of the skin, also known as hemangiomas, are revealed in 1–3% of infants at birth [1, 2], the number increasing by 10% by the first year of life [3]. Hemangiomas, localized in the region of the head and neck, are most commonly encountered in the pediatric practice [1, 2, 4].

A great number of methods are suggested in the literature for the treatment of infants with the so-called hemangiomas: sclera-, hormone-, cryo-, laser-, X-ray therapy, surgical method with application of beta-adrenoblockers, electro-chemical lysis, SHF-destruction, embolization, and others. The difficulty of treating vascular hyperplasias lies in inadequate efficacy and safety of the existing methods of treatment. Some forms of vascular lesions are capable of spontaneous involution [4–10], but during their growth they may reach significant dimensions, which results in serious complications

(ulcerations, scarring, erosive bleedings, deprivation amblyopia). Besides, the process of involution may be incomplete, leading to the residual deformations, scars, preservation of discolored areas with a vascular pattern of the skin [7, 8, 11]. Incomplete rehabilitation of young patients with hemangiomas of the face and neck presents a serious problem of the future social adaptation.

At present, cryodestruction is one of the methods most widely used for treating hemangioma in children. This method is characterized by its availability, simplicity of performing, relative painlessness, and low cost. There are some drawbacks as well: nonselectivity of cryo-action — the whole tissue complex in the exposed focus is involved in the destruction; a small depth of penetration — only 2–5 mm deep; difficulty of the lesion depth control — a slight increase of the cryoapplicator exposure may result in essentially deeper tissue necrosis [11].

For contacts: Ryzhevskiy Dmitriy Vladimirovich, e-mail: drpl@mail.ru

In recent years, method of selective photothermolysis of the vascular skin hyperplasias has been gaining popularity. Physically, this technique is based on absorption of a specific wavelength of light by a structure-target (in case of hemangiomas — by erythrocyte hemoglobin) with the following transformation of the light energy to the thermal one (photothermolysis). This method has an advantage of selective effect on the tissues, and, consequently, their less traumatizing, is simple in performance, and painless. A shortcoming of the selective photothermolysis is a limited depth of penetration of the light flow into the tissues — up to 6 mm, preventing from the effective use of this method for treating voluminous vascular hyperplasias [12]. In order to eliminate the main disadvantage of the selective photothermolysis, the authors suggest supplementing it with a single-step injection of a sclerosing solution into the deep layers of hemangioma.

The aim of the investigation is to evaluate clinical efficacy of the suggested combined method (sclerosing + selective photothermolysis) in treating congenital and neonatal vascular skin hyperplasias of the maxillofacial areas in infants.

Materials and Methods. 1485 infants under 1 year of age with maxillofacial hemangiomas were treated during the period from 2009 to 2013 in the Department of Maxillofacial Surgery of City Children Hospital No.3 and in the Third Laser Surgery Department of the Academician S.F. Fyodorov Intersectoral Research and Technology Complex “Eye Microsurgery”, Cheboksary branch. Separate methods of cryodestruction and selective photothermolysis, as well as a combined method of sclerosing and selective photothermolysis were used for the treatment.

Criteria of the efficacy were as follows:

- 1) reduction of the damaged area (cosmetic result) after the first procedure;
- 2) a number of follow-up visits per year for a continued tumor growth in a group;
- 3) reduction of treatment duration.

A cosmetic result was assessed as good, satisfactory and unsatisfactory. The result was considered to be good if the area involved in the tumor decreased by 50% or more after the first procedure, to be satisfactory — in case of 10–50% reduction, and unsatisfied — when the decrease was less than 10%, or if there was no positive dynamics. The lesion area was measured using a graph paper before the treatment and 1–1.5 months after the first treatment session. The change of the lesion depth was confirmed by an ultrasound examination of hemangioma.

To make the investigation more reliable, only similar clinical cases were selected, and the basic parameter for selection was the height and/or depth of growth of the vascular hyperplasia focus into the healthy tissues (5–9 mm), the lesion area being less important. Thus, the results of treating 250 infants were evaluated in the study.

The study complies with the Declaration of Helsinki (the Declaration was passed in Helsinki, Finland, June, 1964, and revised in October, 2000, Edinburg, Scotland) and was performed following approval by the Ethic Committee of Chuvash State University. Written informed consent was obtained from the patients' parents in accordance with the Federal Law “The Fundamentals of legislation of the Russian Federation on the protection of the health of citizens” of July 22 1993 No.5487-1.

Patients were divided into three groups according to the treatment method: group 1 (n=79) — were treated by cryodestruction; group 2 (n=87) — by selective photothermolysis; group 3 (n=84) — by a combination of selective photothermolysis and sclerosing.

Cryodestruction of hemangiomas was performed in the following way. Cryoapparatus applicator was chosen to match the form of the lesion as much as possible; the apparatus was filled in with liquid nitrogen, and having treated antiseptically the surface of the hemangioma, cryodestruction was performed, the time of exposure being 40–100 s [11]. Immediately after the destruction an “icy” spot appeared, exceeding by its area the size of the applicator. During a few minutes the color of hemangioma restored. In 1.5–2 hours in the region of “freezing” there appeared a flat blister containing serous hemorrhagic substance, the size and form of which corresponded to the “icy” spot. Extensive perifocal edema continued 3–5 days. A dry crust appeared on the 2–3th day (it usually does if managed properly). Separation of the eschar occurred on the 3–4th week. Treatment of large and extensive combined hemangiomas was performed in sessions with 40–45 day interval in-between. In order to limit the growth of the vascular tumor, treatment was begun from the lesion periphery. If hemangioma was complicated with ulceration, suppuration, or bleeding, treatment was started with the correction of complications. In case of ulceration, application of Levomekol dressings, toilet of the wound surface with 3% hydrogen peroxide, and 1% brilliant green were administered. When bleeding was a complication, compressive bandages and hemostatic treatment with 12.5% dicynone: 0.5 ml twice a day, intramuscularly, were instituted.

Selective photothermolysis of hemangiomas was conducted using the Lumanis VasqueLight apparatus (Israel) with 560 nm light filter. After antiseptic cleansing of the hemangioma surface a cold media-gel was applied on its surface covering slightly healthy adjacent tissues as well. Then several light flashes of 4.0 ms duration and 36 J/cm² power were made from the distance of 3–5 mm through the layer of the cold gel. Flashes were stopped as soon as the color of the hemangioma surface became deeply bluish-grey (12 flashes). Three–four hours later a burn blister with serous hemorrhagic content began to form, opening spontaneously the next day after the procedure. The following day the treated surface of the hemangioma was covered with a dry

crust. Separation of the eschar occurred on the 2–3rd week. Complications in the form of suppurations and bleedings were not noted.

Combined treatment was started with sclerosing the vascular hyperplasia focus according to Vernadsky (2% solution of lidocaine in 70% solution of alcohol). Injections were given from 3 points in a fan-like manner, the points of puncture being at a close distance from the periphery of the lesion focus. The amount of the sclerosing agent depended on the hemangioma area — 0.1 ml of alcohol per 1 cm² of the neoplasm. The solution was introduced only into the base of the hemangioma, carefully avoiding its penetration to the superficial layer. Immediately after sclerosing, treatment of the hemangioma with a pulsed light was performed as previously described. To prevent bleeding following phototreatment a compressing plaster dressing moistened with Bepanthen+ ointment was applied to hemangioma. The dressing was removed in a day. Eschar formation occurred in the same terms as following monotherapy by a pulsed light.

Results and Discussion. The analysis of the clinical results of treating congenital and neonatal vascular hyperplasias of the skin in the maxillofacial area in infants (Table 1) showed, that the total number of positive outcomes in combined treatment exceed such in application of only selective photothermolysis and in isolated cryodestruction as well. The difference amounts to 14.77% when the suggested method is compared to selective photothermolysis, and 25.61% — to cryodestruction technique.

A combination of selective photothermolysis and sclerosing reduced essentially an average number of

sessions necessary for steady regression of neoplasms (Table 2).

The combined method of selective photothermolysis and sclerosing reduces the time interval necessary for hemangioma to regress by 4.2 months relative to selective photothermolysis, and by 10.7 months compared to cryodestruction: an average treatment duration is 7.1±2.1, 11.3±4.2, 17.8±3.5 months, respectively.

Two clinical examples are presented for illustration.

Patient A. aged 2 months (Fig. 1, a–d). Mother noticed hemangioma as a bright red point on the 4th week of life for the first time. Then, intensive growth of the neoplasm was going on during two weeks. An attempt was made to remove it by laser coagulation, but the result failed to be a success, and the neoplasm continued to grow.

On the day of admission to our clinic, treatment was performed using the combined method of sclerosing and selective photothermolysis. In 14 days the neoplasia stopped growing, and there appeared foci of regression. The treatment session was repeated. Four weeks later almost complete regression of the lesion and its substitution by a normotrophic scar were observed, though single point peripheral telangiectasias still remained. At the age of 6 months the normotrophic scar was still present, telangiectasias became pale. The treatment result was evaluated as good.

Patient N., 3 months of age (Fig. 2, a, b). By his mother's words, hemangioma had been uniformly growing since its birthday. They sought medical aid because of a left-sided

Table 1
Cosmetic result of treating patients with vascular maxillofacial hyperplasias of the skin after the first treatment session

Result	Cryodestruction		Selective photothermolysis		Combined method of selective photothermolysis and sclerosing	
	Abs. number	%	Abs. number	%	Abs. number	%
Good	18	22.78	31	35.63	60	71.42
Satisfactory	37	46.83	39	44.82	20	23.80
Unsatisfactory	24	30.39	17	19.54	4	4.76
Total	79	100.0	87	100.0	84	100.0

Table 2
A number of follow-up visits per year for the continued tumor growth following the first treatment session

Treatment method	A total number of follow-up	A number of repeated treatment sessions	An average number of repeated treatment sessions
Cryogenic	15	47	3.7
Selective photothermolysis	27	123	4.6
Combined method of selective photothermolysis and sclerosing	6	14	2.6

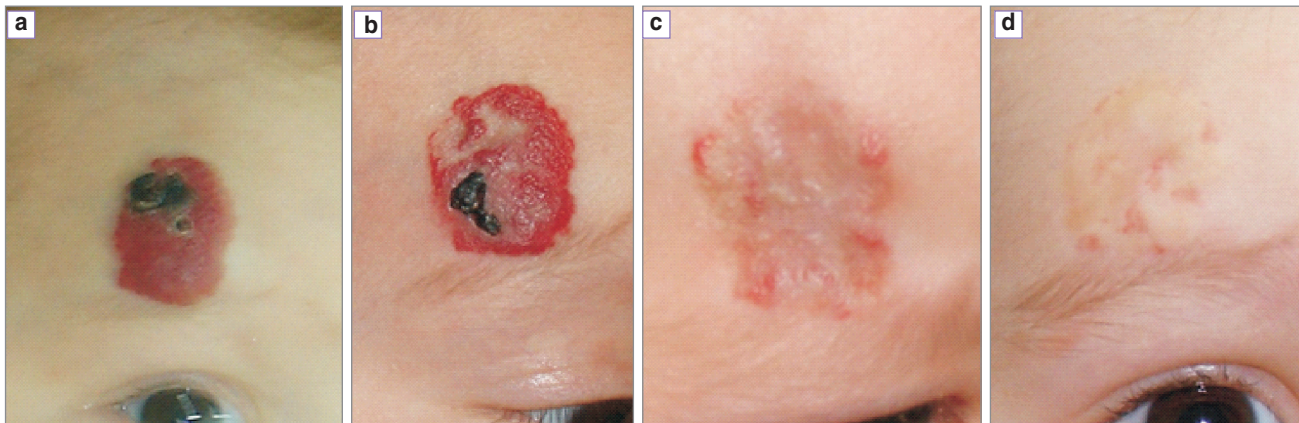


Fig. 1. Patient A., 2 months of age. Dynamics of vascular hyperplasia at the stages of follow-up: *a* — on admission (2 months of age); *b* — 14 days after the first session (2.5 months of age); *c* — following the second session (3.5 months of age); *d* — 3.5 months after the beginning of the treatment (6 months of age)

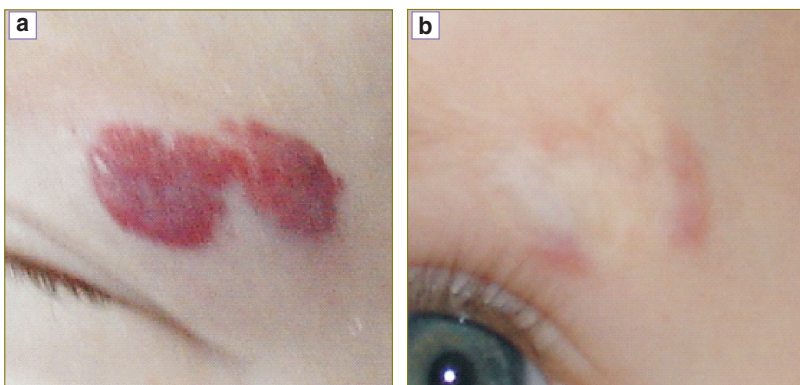


Fig. 2. Patient N., 3 months of age. Dynamics of hemangioma: *a* — on admission (3 months of age); *b* — 5 weeks after a single session of combined treatment using sclerosing and selective photothermolysis (4 months of age)

blepharoptosis. According to ultrasound examination “in the soft tissues of the frontal area on the left in the projection of the upper orbital margin a bulky lesion 48×18×21 mm in size is located, being hypoechogenic, with a nonuniform cellular echostructure, heavily vascularized”. One session of treatment with a combination of sclerosing and selective photothermolysis was conducted. Five weeks later practically complete regression of the neoplasia was noted, signs of blepharoptosis were absent, at the site of the lesion a gentle normotrophic scar was seen.

Successful results of the combined treatment of hemangiomas are easily explained. Despite one-stage destructive action on the neoplasia by a light energy, transforming into the thermal energy, and consequently, into a thermal burn, and also by a chemical reagent with the following chemical burn, a total traumatization of the tissues is not increased, as the points of applying these effects are at different levels of the lesion. Light exposure is restricted by the superficial layers, while a chemical one causes fibrosis of the deeper layers. Thus, a combined effect makes it possible to “process” the lesion in a fuller extent, and the intensity of the exposure, and, respectively, its traumaticity do not increase, but may even be reduced.

The data obtained speaks eloquently about a high efficacy of the combined method of selective photothermolysis and sclerosing of vascular hyperplasia in infants. A mean duration of treatment reduced by 60% compared to cryodestruction, and by 37% relative to the monotherapy with selective photothermolysis.

Conclusion. A combined treatment of congenital and neonatal vascular hyperplasias of the skin in the maxillofacial area in infants proved to be an effective method. Positive cosmetic result after the first exposure session using selective photothermolysis and sclerosing exceeded that of monotherapies: cryodestruction — by 25.61%, and selective photothermolysis — by 14.77%. The quantity of repeated sessions necessary for maximum lesion regression decreases. The method suggested is simple in use, and does not lead to a greater number of complications.

Study Funding and Competing Interest. This study was not supported by any financial sources and there is no topic specific conflict of interest related to the authors of this study.

References

1. *Detskaya khirurgiya: natsional'noe rukovodstvo* [Pediatric surgery: national guidelines]. Pod red. Isakova Yu.F., Dronova A.F.

[Isakov Yu.F., Dronov A.F. (editors)]. Moscow: GEOTAR-Media; 2009; 1053 p.

2. Bruckner A.L., Frieden I.J. Hemangiomas of infancy. *J Am Acad Dermatol* 2003; 48(4): 477–493.

3. Wendling P. Hemangioma risk tied to birth weight. *Skin & Allergy News* 2008; 39(9), http://skin.gcnpublishing.com/fileadmin/content_pdf/archive_pdf/vol39iss9/70640_main.pdf.

4. Enjolras O., Soupre V., Picard A. Classification of superficial vascular anomalies. *Presse Med* 2010; 39(4): 457–464, <http://dx.doi.org/10.1016/j.lpm.2009.07.029>.

5. Arkharov A.M., Solenov V.I., Vozdvizhenskiy I.S., Tsyganov D.I., Butorina A.B., Shafranov V.V., Polyayev Yu.A. Spontannaya regressiya gemangiom kozhi u detey. V kn.: *Peredovye tekhnologii meditsiny na styke vekov* [Spontaneous regression of skin hemangiomas in children. In: Advanced medical technologies at the turn of the century]. Moscow; 2000; p. 363–366.

6. Butorina A.B., Polyayev Yu.A. New technologies in treatment of pediatric hemangiomas. *Detskaya bol'nitsa* 2001; 1: 44–48.

7. Butorina A.B., Polyayev Yu.A., Shafranov V.V., Vel'skaya Yu.I., Vozdvizhenskiy I.S. Hormonal treatment of major

and deep hemangiomas in children. *Voprosy gematologii, onkologii i immunologii v pediatrii* 2004; 3(2): 55–58.

8. Shafranov V.V., Polyayev Yu.A., Prityko A.G., Solenov V.I., Butorina A.B., Tsyganov D.I., Arkharov A.M. Nekotorye teoreticheskie aspekty primeneniya novykh tekhnicheskikh sredstv: v kriokhirurgii gemangiom u detey. V kn.: *Peredovye tekhnologii meditsiny na styke vekov* [Some theoretical aspects of using new technical means in hemangioma cryosurgery in children. In: Advanced medical technologies at the turn of the century]. Moscow; 2000; p. 347–350.

9. Roginskiy V.V., Nadtochiy A.G., Grigoryan A.S., et al. Vascular maxillofacial and neck masses in children — a new view. *Stomatologiya* 2011; 90(4): 71–76.

10. Richard J.A. *Infantile hemangioma*, <http://emedicine.medscape.com/article/1083849-overview>.

11. Golovanov V.N., Pulikov A.C., Yurchuk B.A. Cryodestruction of ulcerous hemangiomas in children. *Detskaya khirurgiya* 2005; 5: 40–42.

12. Vlasov P.G. Selective coagulation of facial vascular lesions with Yachroma-M copper vapor laser. *Angiologiya i sosudistaya khirurgiya* 2001; 7(3): 100–104.