

Thermal Imaging Assessment of Cicatricial Tissue Capabilities in Facioplasty Planning

DOI: 10.17691/stm2015.7.2.16

Received May 12, 2014



N.L. Korotkova, PhD, Senior Researcher, Department of Reconstructive Surgery;

M.G. Volovik, PhD, Senior Researcher, Department of Functional Diagnostics

Privolgzhsky Federal Medical Research Center, Ministry of Health of the Russian Federation,
18 Verkhne-Volzhsкая naberezhnaya St., Nizhny Novgorod, 603155, Russian Federation

The aim of the investigation was to study the capabilities of thermal imaging to estimate the functional reserves of blood supply of facial cicatricial tissues used in skin grafting.

Materials and Methods. Using an infrared thermal imager Thermo Tracer TH-9100 we examined 37 patients with post-burn scars on the face and anterior surface of the neck (total: 126 scar areas planned for flap dissection) and 4 healthy volunteers. After recording a native (original) thermal picture, we carried out a standard local alcohol test with further monitoring of space-time temperature dynamics for 7 min. To develop a criterion of tissue suitability for skin grafting, we calculated $\Delta T = T_{init} - T_{fin}$, where T_{init} was the initial temperature before the test, and T_{fin} — the temperature on the 7th minute of test recovery.

Results. The obtained data on the thermal reaction dynamics of cicatricial tissues enable to evaluate the capability to use these tissues as skin grafting material. The criteria are based on thermal imaging findings of the dynamics of initial temperature recovery of healthy and cicatricial tissues. If the temperature difference by the 7th minute of the examined tissues is below 0.9°C by the end of the alcohol test, the tissues can be used for skin grafting. The temperature recovery lag by more than 1.9°C indicates inapplicability of cicatricial tissues for skin grafting. The temperature difference in the range from 0.9 to 1.9°C should be considered risky.

Conclusion. The developed thermal image technique to assess the functional state of facial cicatricial tissue blood supply enables to determine the criteria of cicatricial tissue availability for minor facioplasty, and differentiate suitable and unsuitable tissues.

Key words: thermal imaging; post-burn facial scars; reconstructive plastic surgery.

Facial deformity related to scarring in burn patients causes severe psychological and social problems. Modern methods of reconstructive and plastic surgery [1, 2, and others] enable to replace extensive scar areas restoring damaged skin that does not always restore the patient's lost appearance [3]. In severe burns the limitations due to the lack of donor sites make the use of local skin grafting — one of the main methods of treatment of facial burns. In these cases, surgeons are compelled to use cicatricial tissue [4, 5].

Therefore, assessment of the suitability of the pathologically altered tissue for local skin grafting remains an urgent task due to poor vascularization of the mature scars, which can be used for skin grafting. Being conversant with the functional reserve of their blood supply is the basis for affirming the prospects for the use of any scarred skin area in plastic surgery.

Assessment of the microcirculation reserves in burn-damaged tissue focuses on the search for adequate assessment methods. Today, laser Doppler flowmetry (LDF) and polarography are the most common methods in medical practice to evaluate the blood supply to cicatricial tissue [6]. The LDF and polarography methods are limited by measurement locality, i.e. only in the zone of the sensor setting. With extensive scarred skin areas, when planning surgical intervention we need

panoramic assessment of the affected area and, above all, differential assessment of areas with various blood supply, we believe infrared thermal imaging to be the best technique for this kind of 'mapping' cicatricial tissue [7].

The validity of the choice of the basic method for the study in this work is confirmed by international practice of thermal imaging for the evaluation of post-burn scars. The first experience of using thermal imaging to solve a similar problem was reported by Lamberty et al. (1979) [8], where the authors assessed the condition of the flaps and predicted their rejection on the ground of thermal imaging findings. A number of studies have described the use of thermal imaging for the assessment of post-burn scarred skin. Thus, surface temperature indices as indicators of skin blood circulation have been proved to be valid [9]. In this study [8] the thermal imaging technique was used to find optimal perforating vessels before flap dissection, LDF serving as a reference method. Recent studies have focused on the experience of the preoperative thermal assessment of perforating vessels in planned skin flaps [10, 11], including a functional test implying cool air blow-off of the skin [12].

At the same time we have found no information on the use of thermal imaging for the assessment of the functional blood-flow reserve of cicatricial tissue, without

For contacts: Korotkova Nadezhda Lenoktovna, e-mail: korotkova-home@mail.ru

the knowledge of which this tissue behavior in the immediate postoperative period is unpredictable.

The aim of the investigation was to study the capabilities of thermal imaging to estimate the functional reserves of blood supply to the facial cicatricial tissue used in skin plastic surgery.

The study was aimed at:

1) investigation of the thermal relief of the face in patients with post-burn scar deformities in comparison with those in subjects with healthy skin;

2) development of a stress test, which allows to evaluate the functional reserve of microcirculation in various areas of the scarred surface of the face;

3) determine the correlation of thermal parameters and clinical data on the state of circulation in cicatricial tissue;

4) assessment of the suitability of the scarred tissue for local skin grafting taking into account the thermal imaging and clinical data.

Materials and Methods. The studies were conducted in the room with the constant temperature of 20–22°C on the thermal imager Thermo Tracer TN-9100 (NEC, Japan), operating in the spectral range of 8–14 μm, having a sensitivity of 0.025–0.03°C with an error of ±1% and the infrared matrix resolution of 320×240 pixels.

Preoperatively, a scheme of the planned cutting lines to form flaps was applied to the patient's face with

the help of a safe marker. The thermal imaging survey began with registration of the native (initial) heat pattern, and then a regional alcohol test was conducted [13] using 70° alcohol sprayed from the distance of 10 cm onto the studied surface of the face. Recovery dynamics of the temperature fields was recorded as a thermovideo of 7 min duration after the refrigerant application. To develop a suitability criterion for different areas of the skin for local grafting we calculated $\Delta T = T_{init} - T_{fin}$, where T_{init} was the initial temperature before the test, T_{fin} was the temperature in the 7th minute of recovery after the test.

A total of 37 patients with post-burn scars on the face and front of the neck (total 126 scar areas planned for flap dissection), including 26 men and 11 women (mean age 27 years), were examined. Four experiments on healthy male volunteers with normal facial skin (mean age 25 years) were carried out to record the dynamics of temperature recovery after the alcohol test in 97 areas of the face and front of the neck (Figure 1).

The study was conducted in accordance with the Declaration of Helsinki (adopted in June 1964 (Helsinki, Finland) and revised in October 2000 (Edinburgh, Scotland)) and approved by the Ethics Committee of the Privolzhsky Federal Medical Research Center. A written informed consent was obtained from each patient.

The clinical assessment of the scarred tissue was

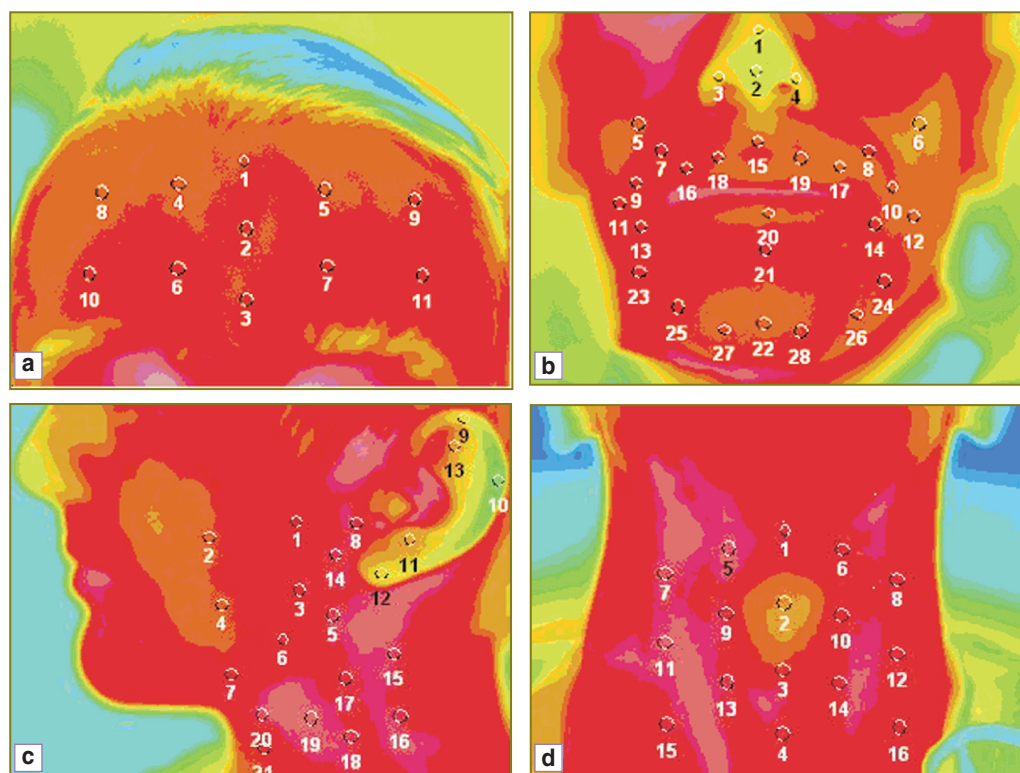


Figure 1. Diagram of the measured areas on the thermal maps of the face and neck in a healthy male subject aged 28: (a) 11 measurement areas on the forehead; (b) 28 areas at full face mapping; (c) 21 areas on the face on the left (by analogy — symmetrical mapping of 21 areas on the right); (d) 16 areas on the front of the neck

based on the Sarygin clinical classification [5], based on the Vancouver scale [14, 15] and providing criteria for availability of scars as a plastic material in reconstructive surgery.

The data analysis was performed on a personal computer using the software for thermal images processing Goratec Thermography Studio (GTS 5.1.1.011). According to the results of each functional test we made up diagrams demonstrating the dependence of temperature on time and performed a statistical analysis of the data in the software environment Statistica 6.1. The differences were considered statistically significant at $p < 0.05$.

Results and Discussion. During the native thermal study of the facial tissue we obtained the data, according to which the use of the known criteria — the temperature difference between the scarred and adjacent healthy tissue more than 1°C [16] proved to be problematic. According to our findings, the scar areas unsuitable for grafting (over 5 by the clinical assessment scale) had a temperature gradient with the intact skin in symmetrical or nearby areas more than 1°C . However, the difference in temperature by 1°C was observed in clinically suitable cicatricial tissue as well as in healthy areas of the facial skin, so this criterion turned out to be insufficient to assess the suitability/unsuitability of cicatricial tissue for plastic surgery. Besides, the use of this criterion presupposes comparing the scar temperature with that of the surrounding intact skin which is rarely possible in burns to the face. This is due to the complex relief of the face and its blood supply.

On the native (initial) thermal maps the healthy facial skin areas have different thermal characteristics with the spread between the maximum and minimum temperature values (with the same adaptation before measurements) in $7\text{--}8^{\circ}\text{C}$; temperature drop may reach $2\text{--}3^{\circ}\text{C}$ when comparing, for example, the area in the projection of the nasolabial triangle with the area on the cheek being only 0.5 cm apart from it.

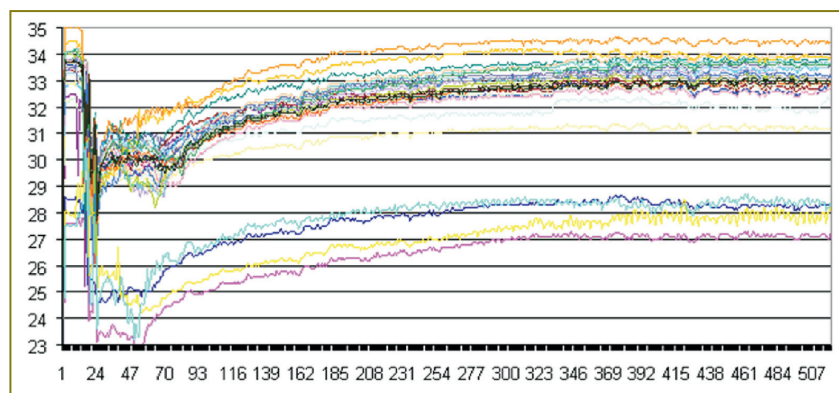


Figure 2. Temperature dynamics after the alcohol test in 28 areas on the face in a healthy subject K., 28 years old. The lower 4 curves are for the nasal area (zones 1–4, See Figure 1), and the rest ones are zones 5–28. The X axis is time (s); the Y axis is temperature ($^{\circ}\text{C}$)

Meanwhile, according to the literature data, the facial areas for large samples are significantly homogeneous by thermal characteristics and they could, if necessary, be used as comparison areas. The study [17] shows that regardless of the unique pattern of subcutaneous blood flow in every person, there are 7 equithermal areas on the face — different areas with a relatively homothermal temperature. However, patients with burns, usually have both the halves of the face injured, making it impossible to compare them. It is also necessary to take into account the established physiological thermoasymmetry of different areas of the facial skin [18]. However, in case of an intact symmetric area we cannot always compare it with the injured one either as the localization on the different halves of the face reduces the accuracy of such studies (rotation of the head, and the need to double the measurement, etc.).

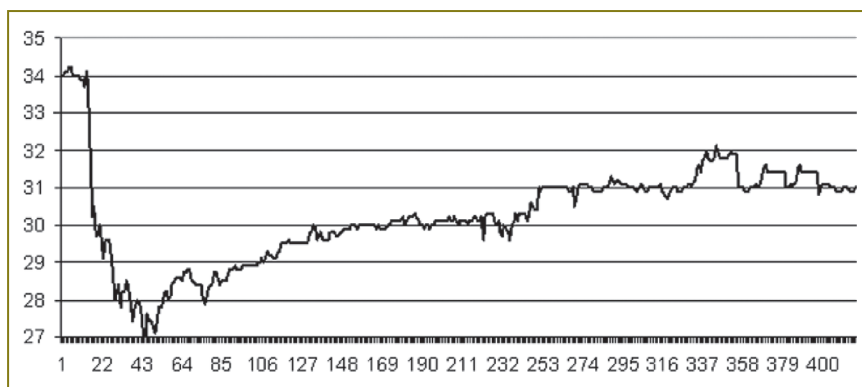
The way out of this situation was the development of a functional stress test, which enables to identify not the so-called temperature norm in the facial thermostopography, but the response norm — typical dynamics of temperature recovery after application of the refrigerant to the skin. The obtained thermograms of response to the alcohol test in 28 areas in the lower part of the face in the healthy subject (Figure 2) showed that the thermal response in all the areas of normal skin, regardless of the initial temperature values is of the same type, and their fluctuation does not exceed 0.2°C , which is comparable to instrument error.

The developed method was used to identify problem areas in cicatricial tissue. On cooling rough scars which are not suitable as a plastic material, such cicatricial tissue was not found to restore the initial temperature by the 7th minute of the study which may indicate blood flow reduction in them. The study of the rough scar showed a lag in the recovery of the initial temperature by 3°C by the 7th minute after the test (Figure 3).

The temperature values (T_{in}) of the scarred facial tissues, suitable, by clinical assessment, to be used in plastic surgery, significantly ($p < 0.001$) reached the values close to the initial ones (T_{init}) by the 7th minute. The difference of temperatures was in range from -0.8 to $+0.9^{\circ}\text{C}$. The difference of temperatures unsuitable for grafting was in the range from 1.9 to 2.5°C . One subject showed the difference in temperature of 5.5 and 8°C in the study of the auricle scars. Their morphological examination after excision diagnosed their keloid character. 24 scar areas were also identified as suitable by the clinical scale, but they could not be used on the face. ΔT values in these areas ranged from 0.9 to 1.9°C when conducting the test.

Statistical data typical for both

Figure 3. A characteristic temperature response to the test in the scar that is unsuitable for skin grafting (by clinical signs). The X axis is time (s); the Y axis is temperature (°C)



Statistical data on thermal response in the cicatricial tissue

Cicatricial tissue	ΔT_{aver}	Standard error	Median	Percentile 10,00000	Percentile 90,00000	p
Suitable for grafting (n=95)	-0.337	0.0467	-0.4	-0.9	0.3	<0.001
Unsuitable for grafting(n=31)	-1.820	0.2543	-1.5	-2.3	-1	<0.001

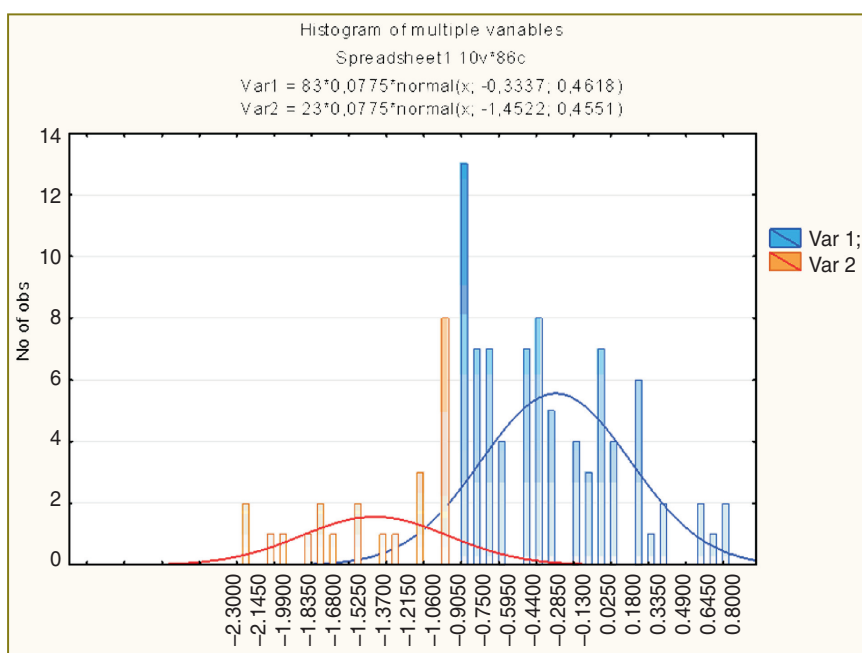
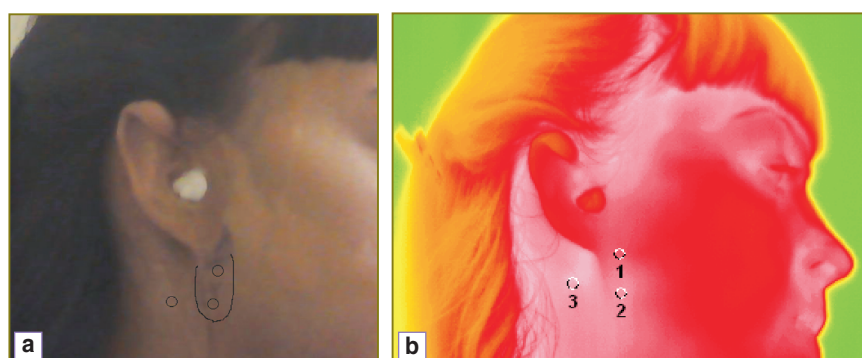


Figure 4. The diagram of the scope for the groups: Var 1 — cicatricial tissue suitable for grafting (n=95), Var 2 — cicatricial tissue, unsuitable for grafting (n=31). The X-axis is the temperature difference for $\Delta T = T_{init} - T_{fin}$ for cicatricial tissue at the end of the alcohol test (°C)

types of scars (clinically suitable and unsuitable for grafting according to the thermal imaging findings) are shown in the Table.

The significance of value differences obtained for the two groups that differ in the quality of blood supply to the skin, is shown in the diagram of temperature distribution (Figure 4).

The data obtained illustrate the following clinical observation.



Patient S.: "Post-burn scar deformity of the right earlobe" is diagnosed.

Figure 5. The appearance of the affected area (right ear) in patient S. with operational (a) and thermal marking (b). 1–3 — areas of temperature measurement

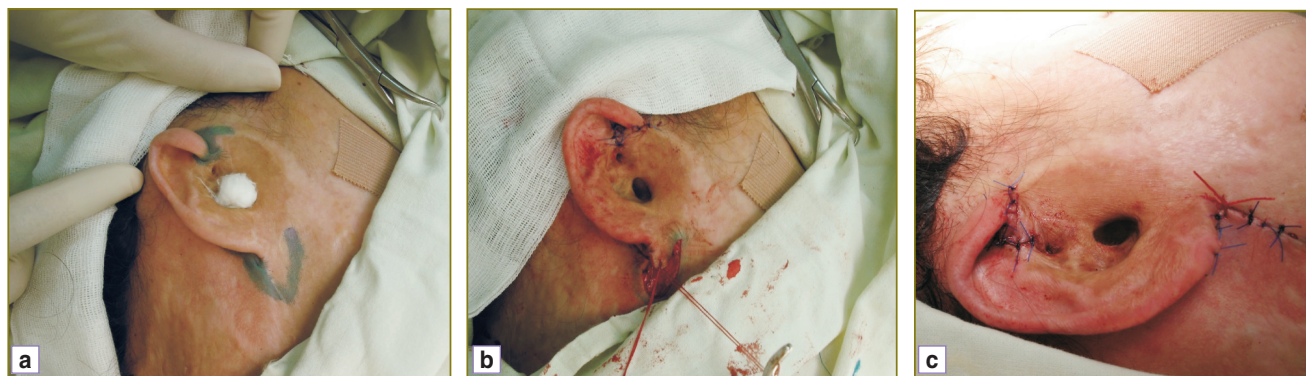


Figure 6. Appearance of the right ear and cicatricial tissue in the parotid region in patient S. during surgery: (a) scar flap mapping performed; (b)–(c) surgery stages

Clinically — fused earlobe, the skin around the auricular lobe is scarred. In the parotid area skin fat flap marking with a proximal base for the formation of the ear lobe was made (Figure 5 (a)). The planned tissue flap is scarred. Thermal imaging with a functional test revealed that the difference in the initial temperature and the temperature by the 7th minute of the cooling test was 0.6°C (proximal region) and 0.8°C (distal region) (Figure 6 (a)–(b)). During surgery the auricular lobe was formed with the use of the studied flap. No postoperative ischemic disorders were observed.

The performed studies did not show all the capabilities of functional thermal imaging. Subtler criteria in accordance with the histological structure of scars, the rate and dynamics of blood flow recovery in the tissues changed by the scarring process are of interest. Intra- and post-operative monitoring of the blood flow in the displaced flaps is also promising to assess the efficacy of the preoperative criteria.

Conclusion. The data on the dynamics of thermal response in cicatricial tissue, indicative of its functional state, allow assessing the use of this tissue as a material for skin grafting. A thermal criterion for assessing the suitability of cicatricial tissue for local plastic surgery was developed. If during the alcohol test the difference between the initial and final temperature achieved by the 7th minute is less than 0.9°C, such tissue can be used as a plastic material. The lag in temperature recovery by more than 1.9°C indicates unsuitability of the cicatricial tissue for skin grafting. Using skin areas, having the temperature difference in the range of 0.9°C to 1.9°C during the alcohol test should be considered risky, in this case it is advisable either to choose alternative methods of plastic surgery or use such cicatricial tissue with the minimum ratio of the length and width of the skin flap.

Study Funding and Conflict of Interest. The study was not funded by any sources, and there is no conflict of interests related to the study.

References

1. D'Souza A.L., Nelson N.G., McKenzie L.B. Pediatric burn injuries treated in US emergency departments between 1990 and 2006. *Pediatrics* 2009; 124(5): 1424–1430, <http://dx.doi.org/10.1542/peds.2008-2802>.
2. Park S. Mestnye i regional'nye kozhnye loskuty. V kn.: *Plasticheskaya i rekonstruktivnaya khirurgiya litsa* [Local and regional skin flaps. In: Facial surgery and reconstructive surgery]. Pod red. Peypla A.D. [Peypla A.D. (editor)]. Moscow: BINOM. Laboratoriya znaniy; 2007; p. 565–585.
3. Korotkova N.L., Ivanov S.Yu. Surgical approach in patients after face burn after-effects. *Annaly plasticheskoy, rekonstruktivnoy i esteticheskoy khirurgii* 2012; 4: 10–17.
4. Dmitriev G.I., Korotkova N.L., Okhotina L.A., Bogos'yan R.A. New surgical technologies in the treatment of sequellae of burns of face and neck. *Travmatologiya zhene ortopediya* 2008; 1(13): 97–99.
5. Sarygin P.V. *Khirurgicheskoe lechenie posledstviy ozhogov shei i litsa*. Avtoref. dis. ... dokt. med. nauk [Surgical treatment of sequellae of burns of face and neck. Abstract for the Doctoral degree of Medical Sciences]. Moscow; 2005.
6. Barkhudarova N.R. *Povyshenie effektivnosti khirurgicheskoy reabilitatsii detey s posleozhogovymi rubtsovymi deformatsiyami i kontrakturami sustavov konechnostey s ispol'zovaniem rekonstruktivno-plasticheskikh operatsiy*. Avtoref. dis. ... kand. med. nauk [Enhancement of efficiency of surgical rehabilitation of children with postburn cicatricial deformities and contractures of extremity joints using reconstructive operation. Abstract for the Dissertation of Candidate of Medical Sciences]. Moscow; 2009.
7. Volovik M.G., Korotkova N.L. Primenenie teplovideniya dlya otsenki krovosnabzheniya posleozhogovykh rubtsov litsa. V kn.: *Trudy X Mezhdunar. konf. "Prikladnaya optika-2012"* [Thermal imaging application to estimate blood supply of after burn facial scars. In: Proceedings of X International Conference "Applied optics-2012"]. Saint Petersburg; 2012; p. 136–140.
8. Tenorio X., Mahajan A., Montandon D., Pittet B. Dynamic infrared imaging in reconstructive surgery. *Plastic and Reconstructive Surgery* 2005; 116(3): 147–149, <http://dx.doi.org/10.1097/00006534-200509011-00123>.
9. Pau H.W., Sievert U., Graumüller S., Wild E. Incisions for cochlear implant flaps and superficial skin temperature.

Skin temperature/blood circulation in CI flaps. *Otolaryngol Pol* 2004; 58(4): 713–719.

10. Chubb D., Rozen W.M., Whitaker I.S., Ashton M.W. Images in plastic surgery: digital thermographic photography (“thermal imaging”) for preoperative perforator mapping. *Ann Plast Surg* 2011; 66(4): 324–325, <http://dx.doi.org/10.1097/SAP.0b013e31820bcc5e>.

11. de Weerd L., Weum S., Mercer J.B. Dynamic infrared thermography: a useful tool in the preoperative planning of deep inferior epigastric perforator flaps. *Ann Plast Surg* 2012; 68(6): 639–640, <http://dx.doi.org/10.1097/SAP.0b013e318244413a>.

12. Ring E.F.J., Ammer K. Infrared thermal imaging in medicine. *Physiol Meas* 2012; 33(3): R33–R46, <http://dx.doi.org/10.1088/0967-3334/33/3/R33>.

13. Volovik M.G., Vodop'yanov K.A. Thermal imaging quality control of prolonged regional anesthesia in children. *Rossiyskiy neyrokhirurgicheskiy zhurnal im. A.L. Polenova* 2011; 3(special issue): 18–21.

14. Nedelec B., Shankowsky H.A., Tredget E.E. Rating the resolving hypertrophic scar: comparison of vancouver scar

scale and scar volume. *J Burn Care Rehabil* 2000; 21(3): 205–212, <http://dx.doi.org/10.1097/00004630-200021030-00005>.

15. Mustoe T.A., Cooter R., Gold M.H., Hobbs R., Ramelet A.-A., Shakespeare P., et al. International clinical recommendations on scar management. *Plastic and Reconstructive Surgery* 2002; 110(2): 560–571, <http://dx.doi.org/10.1097/00006534-200208000-00031>.

16. Okhotina L.A. *Khirurgicheskaya reabilitatsiya bol'nykh s rubtsovymi deformatsiyami i kontrakturami shei posle ozhoga*. Avtoref. dis. ... kand. med. nauk [Surgical rehabilitation of patients with cicatricial deformities and contractures of neck after burns. Abstract for the Dissertation of Candidate of Medical Sciences]. Nizhny Novgorod; 1997.

17. Cheremisina E.N., Basha N.S. Personal identification by thermal imaging of face: the current state, development prospects. *Sistemnyy analiz v nauke i obrazovanii* 2012; 2. URL: <http://www.sanse.ru/archive/24>.

18. Durnovo E.A., Potekhina Yu.P., Marochkina M.S., Mochalova D.A. Development and analysis of thermal maxillofacial mapping according to sex and age. *Rossiyskiy stomatologicheskiy zhurnal* 2013; 3: 4–9.