

# Microfocus X-ray for Electrode Array Position Control During Cochlear Implantation

DOI: 10.17691/stm2017.9.3.05

Received February 14, 2017



**V.N. Sokolova**, Junior Researcher, Research and Clinical Unit of Audiology, Hearing Aid, and Hearing and Speech Rehabilitation<sup>1</sup>;

**Diab Hassan Mohamad Aly**, MD, DSc, Professor, Department of Otorhinolaryngology<sup>2</sup>;  
Head of the Research and Clinical Unit of Ear Diseases<sup>1</sup>;

**N.N. Potrakhov**, DSc, Professor, Head of the Department of Electronic Devices<sup>3</sup>;

**A.Y. Gryaznov**, DSc, Professor, Deputy Head of the Department of Electronic Devices for Academic Affairs<sup>3</sup>;

**N.E. Staroverov**, 6th-year Student<sup>3</sup>;

**A.Y. Vasilyev**, MD, DSc, Corresponding Member of the Russian Academy of Sciences, Professor,  
Department of Radiodiagnosis<sup>4</sup>

<sup>1</sup>Scientific Clinical Center of Otorhinolaryngology, Federal Medico-Biological Agency of Russia,  
30, build 2 Volokolamskoye Shosse, Moscow, 123182, Russian Federation;

<sup>2</sup>Pirogov Russian National Research Medical University, 1 Ostrovitianov St., Moscow, 117997,  
Russian Federation;

<sup>3</sup>Saint Petersburg Electrotechnical University "LETI", 5 Professor Popov St., Saint Petersburg, 197376,  
Russian Federation;

<sup>4</sup>Moscow State University of Medicine and Dentistry named after A.I. Evdokimov, 20/1 Delegatskaya St.,  
Moscow, 127473, Russian Federation

**The aim of the investigation** was to determine the possibilities of microfocus X-ray for assessing the anatomy of the temporal bone and the position of an electrode array during cochlear implantation.

**Materials and Methods.** A human temporal bone, human skull, porcine head, in the temporal bones of which an electrode array of the cochlear implant was inserted, were prepared for the experiment. Reference radiographs were obtained by means of radiography and multislice computed tomography. Microfocus X-ray images were obtained using portable X-ray devices of the PARDUS-R family (ELTECH-Med, Russia).

**Results.** The quality of the images obtained was analyzed on the basis of several criteria: the ability of detailed electrode array visualization, presence of artefacts, visual evaluation of the image quality, etc. The modiolus, osseous spiral lamina, and electrode array contacts were clearly presented in the temporal bone and human skull. The image quality was evaluated as high and very high. The best results for the electrode array position control in the porcine cochlea were received in the upgraded transorbital-intraoral projection. Taking into consideration the data obtained, a method of acquiring X-ray images of a cochlear implant was elaborated.

**Conclusion.** The advantage of digital microfocus X-ray for the assessment of electrode array position in the temporal bone has been proved. The radiography with a microfocal radiation source provides a high resolution at a minimal exposure dose and absence of artefacts from the metal implant parts.

**Key words:** microfocus radiography; cochlear implantation; portable X-ray device.

A normal functioning of the hearing analyzer plays an important role in maintaining the quality of life in adults and is of special value for general, psychological, and speech development of a child [1–3]. At present, the main method of rehabilitation of patients with congenital and acquired sensorineural IV degree hearing loss and deafness is cochlear implantation. In the course of surgical stage, an electrode array of the cochlear implant is placed into the patient's cochlea.

A gained experience, implementation of advanced technologies, and improvements in surgical techniques for this kind of intervention make it safe and successful.

Nevertheless, the risk of incorrect position of an electrode array remains, especially in patients with the anomaly of cochleovestibular system. Cases of extracochlear position of the electrode array amount to 0.17–2.12% [4]. Incorrect electrode array position may result in a failure to restore the auditory function, the necessity of a revision operation and, in some cases, reimplantation, and in traumas to the structures adjoining the cochlear as well.

An intraoperative and/or postoperative radiological control of the electrode array position provides timely detection of this situation. Currently existing methods

**For contacts:** Vera N. Sokolova, e-mail: vera.nova@gmail.com

have their own advantages and disadvantages. Application of X-ray units of C-arm type or cone beam computed tomography scanners is referred to the intraoperative imaging techniques. Cone beam computed tomography allows visualization of the temporal bone structure with high contrast and spatial resolution but this technique has not yet been widely adopted since the algorithms of image acquisition and reconstruction during cochlear implantation are only being developed. In general, the drawbacks of the modern methods of visualization are connected with the technical difficulties of their application directly in the operating room, and the most common methods of multispiral computed tomography, cone beam computed tomography, and transorbital radiography can be used mainly postoperatively. Besides, all known visualization means in cochlear implantation provide a sufficiently high radiation dose [5]. A high cost of these methods is also an important factor. The necessity of intraoperative control of the electrode array position in the cochlea, especially in patients with cochleovestibular pathology, as well as the feasibility of using more informative, sparing and convenient methods of radiological diagnosis determine the relevancy of developing and implementing into practice new methods of radiological examination in otosurgery, especially during cochlear implantation.

Microfocus X-ray may serve as an alternative modality, which is rather widely being used in recent years in various fields of medicine. This method of obtaining radiographic images has been developed by Russian specialists [6, 7]. The source of X-ray radiation in such microfocal radiographic units has the size of a focal spot less than 0.1 mm. The less is the size of the focal spot, the higher is the resolution of the radiographic image, and respectively, the structure of the object

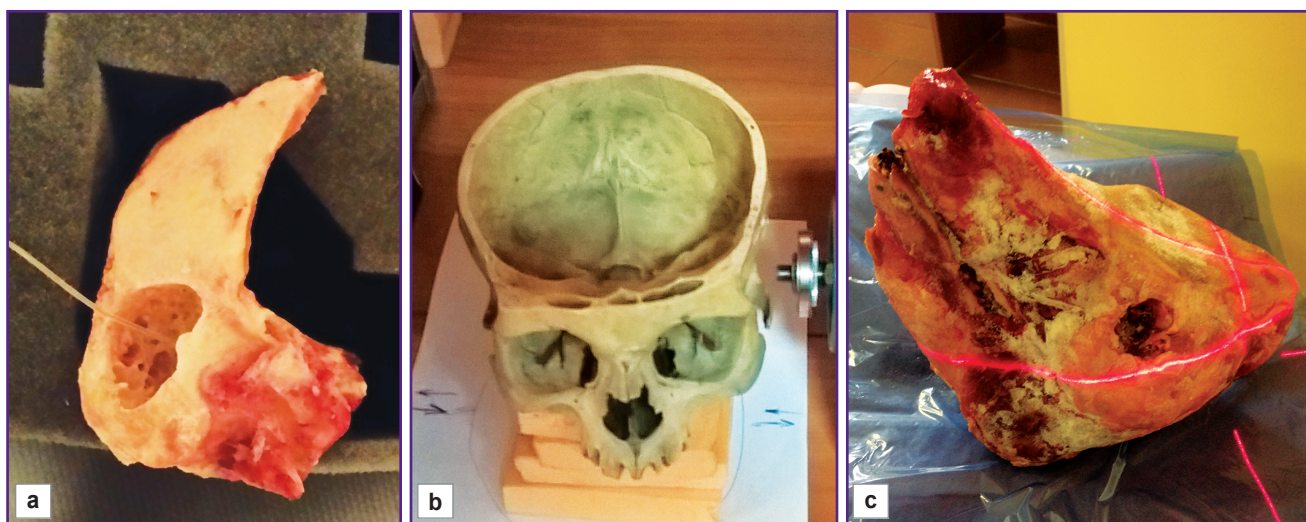
being diagnosed is better visualized. The developed microfocal X-ray devices of PARDUS-R family (ELTECH-Med, Russia) have small dimensions, making their intraoperative use feasible. And an average dose of patient irradiation per one spot radiograph, for example, in dentistry [8] does not exceed 1  $\mu$ Sv. Besides, already at a distance of 1 m, maximal dose rate for medical staff, normalized to the operating load of the PARDUS-R devices, meets the requirements of Sanitary Norms and Rules 2.6.1192-03.

**The aim of the investigation** was to ground experimentally the feasibility of microfocal radiography application and to determine its efficiency in obtaining radiological images during evaluation of the correct electrode array position in the spiral canal of cochlea in the temporal bone.

**Materials and Methods.** The specimens of a temporal bone, human skull and porcine head with soft tissue were prepared for the experimental study. After antromastoidotomy and posterior tympanotomy, an electrode array of the cochlear implant with the length of the working part of 26 mm and 20 electrode contacts, with the diameter in the base and extreme point of 1.07 and 0.5 mm, was introduced into the scala tympani of the cadaver temporal bone. The distance between the electrodes was equal to 0.7 mm (Figure 1 (a)). Access to the medial wall of the tympanic cavity was made via the external acoustic meatus of the human skull (Figure 1 (b)) and porcine head (Figure 1 (c)). Electrode arrays with the active part length of 26.4 mm, 12 stimulating channels and the distance between them of 2.4 mm, were inserted through the round window in the spiral canal of the cochlea.

The study was conducted according to the following scheme:

multispiral computed tomography of the objects using



**Figure 1. Insertion of the cochlear implant electrode array:**

(a) into the cochlea of the cadaver temporal bone; (b) via the external auditory meatus of the human skull and (c) the porcine head with soft tissues

a stationary Brilliance 64 unit (Philips, Netherlands) for the correct intracochlear positioning of the electrode array;

radiography of the temporal bone specimen using a stationary Luminos dRF unit (Siemens, Germany) to obtain a reference skiological image;

microfocus radiography of the temporal bone and human skull specimens using portable PARDUS-R devices (ELTECH-Med, Russia) to determine physical and technical parameters of image acquisition and necessary positioning manipulations for evaluation of the potentialities of this method for electrode array positioning and differentiation of the anatomical structures;

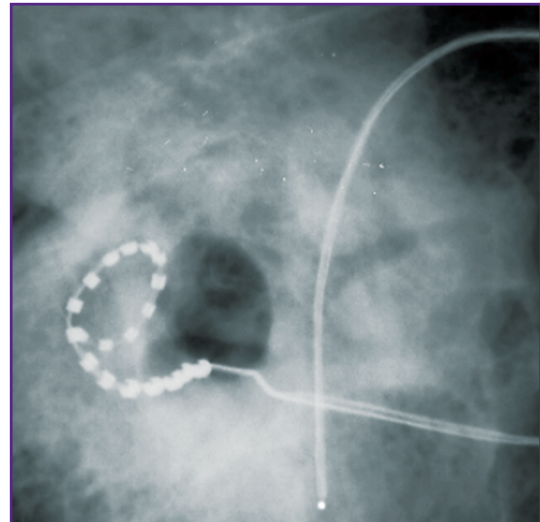
microfocus cone beam tomography to obtain the images of the cadaver temporal bone;

microfocus radiography of the porcine head using the devices of the PARDUS-R family for the development of intraoperative method of obtaining images of the electrode array in the cochlea.

**Results and Discussion.** In the course of the experimental study, microfocus radiographs of different examined objects were obtained using PARDUS-R devices in various modes of exposure and positioning with visualization on the digital image detector. The following exposure parameters for microfocus radiography of the temporal bone and human skull were used: 60 kV voltage, 3–6 s exposure time, 60 mm distance from the X-ray cone to the object. The quality of the images was analyzed by several criteria: visual assessment of the quality of the anatomical landmark images of the temporal bone, position of the electrode array relative to the cochlea structures, detection of separate electrode contacts, presence of artefacts, general impression from the image quality.

Eight microfocus radiograms of the temporal bone specimen were obtained. On the whole, the electrode array on the obtained radiographs was differentiated along the whole length, its contours were sharp, separate electrodes were clearly distinguished, artefacts on the images were absent. The quality of the radiographs was estimated as good. We tried to find conditions for taking images, at which a good visualization of the whole array as well as separate electrode contacts could be achieved. Various projections were chosen in such a way that it would be possible to estimate the position of electrodes in the basal coil of the cochlea in the form of the perfect circle, and the position of electrodes relative basal and middle coil of the cochlear. On the radiograph presented as an example (Figure 2) on the background of the petrous part of the temporal bone, three semicircular canals, vestibule, are clearly defined. On the radiograph, the electrode array located in the basal coil of the cochlea has a round shape. Electrodes in the apical part are distinctly visualized.

Microfocus method of imaging provides better visualization of bone structures, a higher degree of discernibility of image details, and the ability of direct



**Figure 2. Microfocus radiograph of the temporal bone specimen**

magnification of the object image in comparison with the reference radiograms acquired on the stationary unit.

During the study, 6 radiographs of the human skull with the electrode array inserted in the cochlea were obtained. Three projections were chosen: transorbital, lateral, and oblique. On the images taken in the transorbital projection, the electrode was visible along the whole cochlea length, taking the form of a perfect circle, with a sharp differentiation of separate electrode contacts. When lateral projection was used, detailed differentiation of separate electrode contacts was not achieved, possibly, due to the effect of summation. Further elaboration of positioning variants for this projection will permit visualization of electrode array position relative the basal and middle coil of the cochlea. In general, the obtained radiographs of the skull were estimated as good and satisfactory.

Images of the temporal bone were acquired using a combination of microfocus tube and its 360° movement around the X-ray detector, i.e. using microfocus tomography technique (Figure 3). The proposed method makes it possible to visualize the temporal bone structures and separate electrodes of the cochlear implant. The microfocal images were estimated as good and very good, permitting the detailed study of the temporal bone anatomic landmarks, position of the electrode array relative to the walls of the cochlear canal, the depth of its insertion.

As a phantom of the patient's head with imitation of soft tissues was not available, the experiment was further performed on the porcine head, in the cochlea of which the electrode array was inserted (See Figure 1 (c)). To control the electrode array position, the following parameters of X-ray shooting were used: 70 kV voltage, 5 s exposure time. Six microfocus radiograms were obtained. The best results were received in the

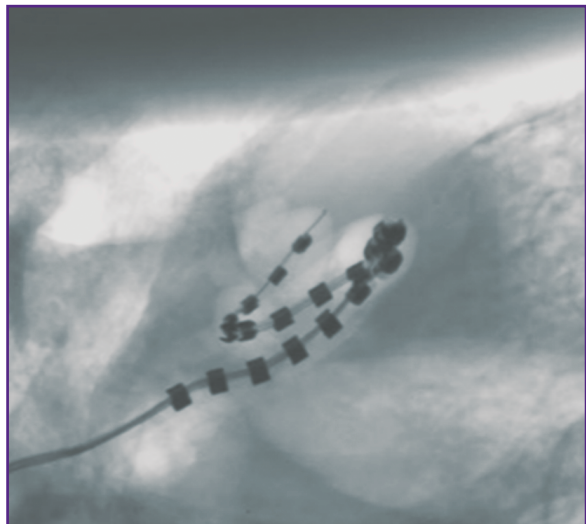


Figure 3. Temporal bone radiograph obtained by microfocus tomography technique

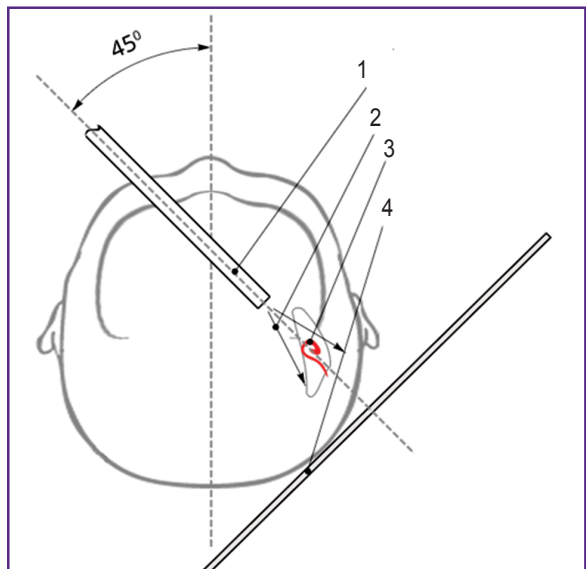


Figure 4. Schematic representation of intraoral radiography with the control of the electrode array position:

(1) X-ray tube anode; (2) X-ray flux; (3) electrode array; (4) X-ray detector

upgraded transorbital-intraoral projection (Figure 4). It was realized using a special microfocus X-ray tube with a remote target attached to a long anode tube. Application of a microfocus radiation source provides the opportunity to obtain magnified radiographs with a satisfactory sharpness and contrast in the transorbital

projection changing the position of the radiation source. Placement of the anode into the oral cavity results in better visualization of the electrode array and more precise assessment of its position.

The analysis of the experimental data enabled us to develop a method of acquiring X-ray images of a cochlear implant (application for a patent RF No.2016126444 of 01.07.2016). Radiography with microfocus radiation source provides a high resolution at a minimal exposure dose and absence of artefacts from the metal implant parts. The exposure of one radiograph was 1–2 orders of magnitude lower than in all other diagnostic methods.

**Conclusion.** The experimental study conducted showed great potentialities and perspectives of microfocus X-ray for the assessment of electrode array position in the temporal bone. The acquired microfocus images can serve as a basis for creating a new class of diagnostic X-ray equipment: radiological units for intraoperative imaging during cochlear implantation, which may improve the basic method of rehabilitation of patients with IV degree of hearing loss and deafness.

**Study Funding.** The work was not supported by any financial sources.

**Conflicts of Interest.** The authors declare no conflicts of interest.

#### References

1. Starokha A.V., Balakina A.V., Litvak M.M., Knipenberg A.E., Shcherbik N.V., Druzhinin A.I. Cochlear implantation prevalence in elderly. *Byulleten' sibirskoi meditsiny* 2014; 13(1): 122–128.
2. Kral A., O'Donoghue G.M. Profound deafness in childhood. *N Engl J Med* 2010; 363(15): 1438–1450, <https://doi.org/10.1056/nejmra0911225>.
3. Tavartkiladze G.A. *Kokhlearnaya implantatsiya* [Cochlear implantation]. Moscow; 2000.
4. Tange R.A., Grolman W., Maat A. Intracochlear misdirected implantation of a cochlear implant. *Acta Otolaryngol* 2006; 126(6): 650–652, <https://doi.org/10.1080/000164805000445206>.
5. Ivanova I.V. Diagnostic radiology in cochlea implant surgery: current trends and future development (literature review). *Radiologiya — praktika* 2014; 6(48): 50–58.
6. Vasilyev A.Yu., Potrahov N.N., Balitskaya N.V., Boichak D.V. Digital X-ray technologies in the evaluation of bone structure. *Vestnik rentgenologii i radiologii* 2012; 5: 22–25.
7. Bulanova I.M., Smirnova V.A., Boichak D.V. Digital small dose microfocal radiography in the characteristic of a bone fabric (clinical and experimental research). *Radiologiya — praktika* 2011; 4: 13–20.
8. Prokhvatilov G.I., Potrahov N.N., Grebnev G.A., Gordeev S.A., Gryaznov A.Yu. A compact digital radiodiagnostics complex "PARDUS-Stoma". *Voennomeditsinskiy zhurnal* 2009; 330(1): 73–76.