

# Laser Video Fluorescence Diagnosis of Stomach Diseases

DOI: 10.17691/stm2018.10.4.05

Received April 3, 2018



**M.V. Loshchenov**, PhD, Researcher, Laboratory of Laser Biospectroscopy<sup>1</sup>;  
**V.V. Levkin**, MD, DSc, Professor, Department of Faculty Surgery No.1<sup>2</sup>;  
**A.F. Chernousov**, MD, DSc, Professor, Academician of Russian Academy of Sciences,  
 Head of the Department of Faculty Surgery No.1<sup>2</sup>;  
**N.A. Kalyagina**, PhD, Researcher, Laboratory of Laser Biospectroscopy<sup>1</sup>; Researcher<sup>3</sup>;  
**S.S. Kharnas**, MD, DSc, Professor, Department of Faculty Surgery No.1<sup>2</sup>;  
**V.Y. Zavodnov**, MD, PhD, Head of the Interclinical Endoscopic Unit<sup>2</sup>;  
**K.G. Linkov**, PhD, Senior Researcher, Laboratory of Laser Biospectroscopy<sup>1</sup>;  
**G.H. Musayev**, MD, DSc, Professor, Department of Faculty Surgery No.1<sup>2</sup>;  
**A.V. Egorov**, MD, DSc, Professor, Department of Faculty Surgery No.1<sup>2</sup>;  
**R.V. Karpova**, MD, DSc, Professor, Department of Faculty Surgery No.1<sup>2</sup>;  
**V.K. Rybin**, PhD, Associate Professor, Department of Faculty Surgery No.1<sup>2</sup>;  
**T.V. Khorobrykh**, MD, DSc, Professor, Department of Faculty Surgery No.1<sup>2</sup>

<sup>1</sup>Prokhorov General Physics Institute of the Russian Academy of Sciences, 38 Vavilov St., Moscow, 119991, Russia;

<sup>2</sup>I.M. Sechenov First Moscow State Medical University (Sechenov University), 8/2 Trubetskaya St., Moscow, 119991, Russia;

<sup>3</sup>National Research Nuclear University MEPhI, 31 Kashirskoe Shosse, Moscow, 115409, Russia

**The aim of the study** was to assess the efficiency of the method for registration of video fluorescence of 5-ALA-induced protoporphyrin IX in stomach and esophagus diseases, to adapt it for clinical conditions, i.e. for conducting differential diagnosis and detecting precancer conditions, and to formulate recommendations on the best photosensitizer doses and time of application in order to make the diagnostic procedure for these diseases more accurate.

**Materials and Methods.** Registration of fluorescence for diagnostic purposes was performed on 57 patients with gastropathology (mainly with stomach cancer) with the help of single-channel (n=50) and dual-channel (n=7) laser video fluorescence registration systems. The study was performed using 5-aminolevulinic acid (5-ALA) (Alasens). 39 endoscopic, 18 intraoperative/laparoscopic investigations, and 7 studies on the macropreparation have been performed.

**Results.** When both systems were used, no fluorescence was registered in cases of stomach ulcer, chronic gastritis, massive tumor necrosis and blood admixture in the stomach as well as in the patient with subcompensated stenosis and a stented output section of the stomach without serous membrane invasion and low 5-ALA concentration. In all other cases, a distinct fluorescence was recorded, the data of which may be used for establishing exact diagnosis and choosing further treatment tactics.

**Conclusion.** Laser video fluorescence technique is a promising method for differential diagnosing and definition of the tumor extension process in the stomach and esophagus which can be used as an express method in diagnostically complex cases.

**Key words:** gastric cancer; 5-aminolevulinic acid; Alasens; laser diagnosis; video fluorescence; laser video fluorescence diagnosis.

## Introduction

Gastric cancer is the third leading cause of death among oncological diseases worldwide, with 5-years survival being only in 28.3% of patients [1]. Timely diagnosis is well-known to play an important role in the outcomes of this nosology treatment.

The main method of gastric cancer diagnosis providing morphological confirmation is endoscopic examination [2]. At present, various technologies making standard gastroscopy more effective and precise are being developed. The method based on registration of fluorescence with the possibility of investigating the effect

of the exciting light on the tumor tissue is an example of such technology. The main idea of the method is registration of photons emitted by the substance when it absorbs laser radiation quanta during their transition from the excited to ground state. This process was called fluorescence and can be registered visually or with the help of special equipment. These methods have already been used to diagnose and treat tumors of different localizations [3–7]. Their application in gastroenterology will potentially make standard endoscopic examination for cancer much more effective.

Synthesis of 5-aminolevulinic acid (5-ALA) provided new opportunities for laser fluorescence diagnosis [8].

**Corresponding author:** Vladimir V. Levkin, e-mail: doctor-levkin@mail.ru

This compound is not a photosensitizer but it induces synthesis and accumulation of photoactive protoporphyrin IX (PP IX), a heme precursor, in tumor cells. About 350 mg of 5-ALA is synthesized daily in the human body providing normal hematopoiesis. Tumor cells are known to be capable of increased accumulation of PP IX in the presence of exogenous 5-ALA [9–12]. This is believed to be associated with a greater activity of the enzymes of the heme synthesis initial stage in the tumor cells and with the deficit of ferrochelatase in them (the enzyme converting PP IX into heme) [13, 14]. Thus, the fluorescence intensity of the malignant tumor relative to the adjacent tissues appears to be essentially higher providing a better diagnostic effectiveness of this method compared to autofluorescence. Rapid metabolism of 5-ALA practically fully excludes phototoxicity.

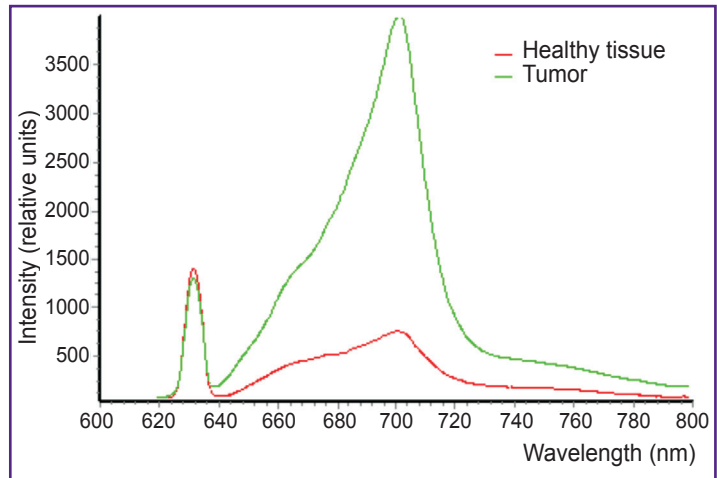


Figure 1. Typical spectra of photoactive 5-ALA-induced protoporphyrin IX

Alasens preparation is convenient for peroral application, does not have specific contraindications. The optimal time interval for the diagnosis (irrespective of the character of examination — endoscopic, laparoscopic, or intraoperative) is 2–4 h after its intake. The optimal dose of the drug is 20 mg/kg.

The intensity of 5-ALA-induced fluorescence is so high (Figure 1) that it can be registered not only with spectrum analyzers but with special highly sensitive cameras as well, opening up great perspectives. However, the problem of performing diagnostic investigations of the upper sections of the gastric tract with the help of gastroscopic video registration systems has not yet been solved.

The aim of the study was to assess the efficiency of the method for registration of video fluorescence of 5-ALA-induced protoporphyrin IX in stomach and esophagus diseases, to adapt it for clinical conditions, i.e. for conducting differential diagnosis and detecting precancer conditions, and to formulate recommendations on the best photosensitizer doses and time of application

in order to make the diagnostic procedure for these diseases more accurate.

### Materials and Methods

Two prototypes of fluorescence image analyzers (single- and dual-channel) compatible with a standard gastroendoscope and having no analogs in the world have been devised by the authors. These prototypes are also compatible with laparoscopic equipment enabling surgeons to assess intraoperatively/laparoscopically the extension of the tumor process and even to detect foci of microcanceromatosis [8].

The UFF-630/675-01 system, a single-channel version (Biospec, Russia), consists of a highly sensible black-and-white camera (0.0003 lux) and a system of optical filters allowing us to conduct investigations not only in the visible range but also to register laser-excited fluorescence (Figure 2). A special adapter is used to connect a gastroscope waveguide to the LED laser waveguide.

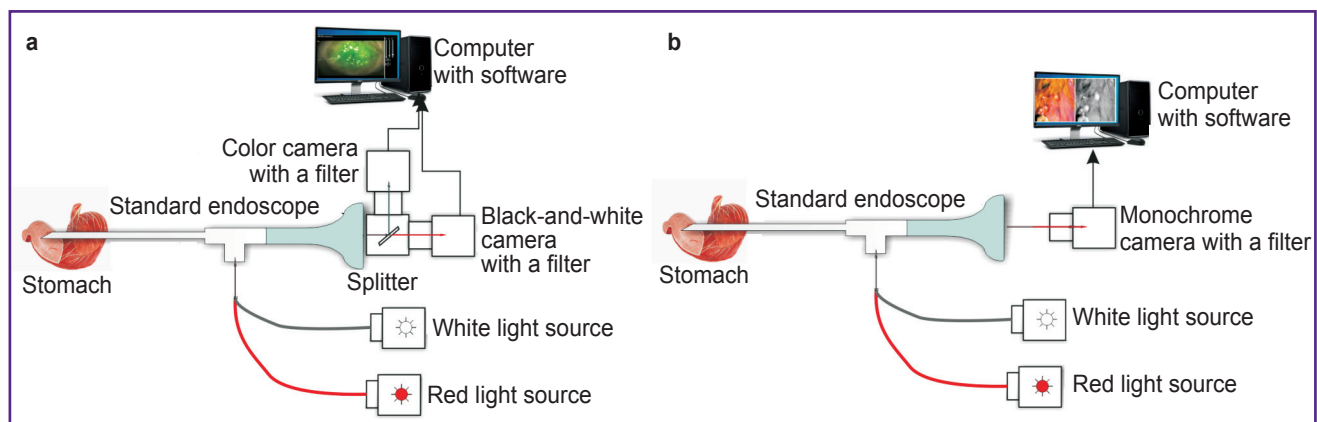


Figure 2. Schematic diagram of UFF-630/675-01 system for video fluorescence diagnosis: (a) single-channel version; (b) double-channel version

The double-channel system allows examination of the gastric mucous membrane in the usual white light and simultaneous exposure of it to laser radiation with subsequent fixation of fluorescence in a specified color (for example, green). Additionally, the diagnostic contrast coefficient is being concurrently measured making spectroscopy unnecessary (Figures 2, 3).

The investigations had been performed in N.N. Burdenko Clinic of Faculty Surgery and Interclinical Endoscopic Unit of I.M. Sechenov First Moscow State Medical University from 2003 till 2017. The work complies with the principles of the Helsinki Declaration (2013) and was approved by the Ethics Committee of I.M. Sechenov First Moscow State Medical University. Written informed consent was obtained from every patient. Alasens solution in a single dose of 10–25 mg/kg was administered to the patients perorally 2–4 h before the supposed examination (endoscopic, laparoscopic, or intraoperative). No photo dermatosis and toxic allergic reactions to the introduced preparation were noted. If a patient was on antacid preparations, H<sub>2</sub>-histamine blockers or proton-pump inhibitors, they were discontinued not less than 2 days before the fluorescence diagnosis.

Registration of endoscopic video fluorescence in 50 patients was done by means of the single-channel device — an attachment for a standard endoscope. A total of 35 endoscopic video fluorescence examinations of gastric mucous membrane, 15 intraoperative, and 7 video fluorescence examinations of the macropreparation were performed using this system.

Seven patients were examined using the updated

double-channel system which, as mentioned above, makes it possible to examine patients in the usual white light with simultaneous exposure to laser radiation and subsequent fixation of fluorescence in a specified color (for example, green). All in all, 4 video fluorescence gastroscopies, 1 laparoscopic, and 2 intraoperative examinations were performed using this system.

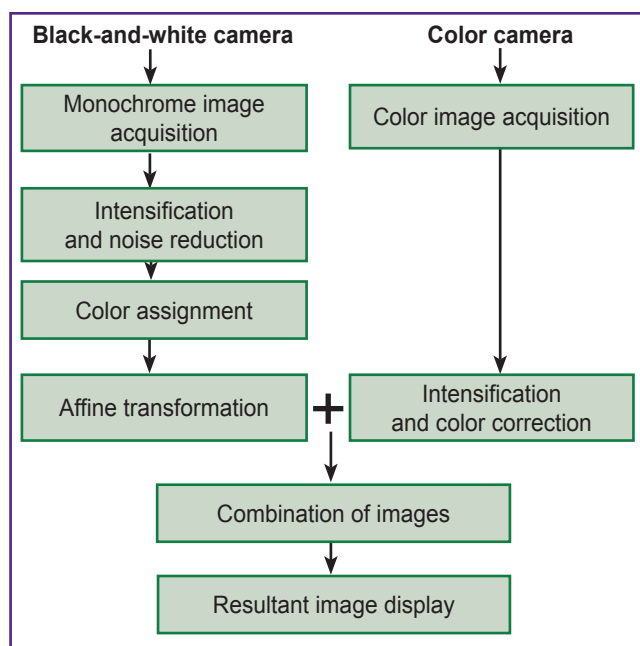
Similar methodology was used for intraoperative/laparoscopic investigation of the tumor process extension (n=18) aimed at detecting and verifying areas of canceromatosis. A standard laparoscope and the described systems were used for this purpose. The laparoscope was located at a distance of 1–3 cm from the surface being explored. Gastric walls on the side of the serous membrane (omental bursa was opened if necessary), liver, paracolic gutters, peritoneum of the anterior abdominal wall, loops of small intestine, and small pelvis were sequentially examined. If no more than 4–5 h passed from the time of Alasens intake till subtotal gastric resection or gastrectomy, a macropreparation was investigated both on the side of the mucous and serous membranes.

### Results

Fluorescence images of the stomach examined endoscopically with the single-channel system showed distinct fluorescence of the tumor in 21 of 24 patients (87.5%) (see the Table). In 3 patients, fluorescence was absent due to subtotal damage of the stomach resulted in insufficient degree of Alasens absorption. Accordingly, the coefficient of diagnostic contrast at spectroscopy was low in these patients. In 4 patients (2 with ulcers, 1 with chronic atrophic gastritis, and 1 with stomach polyp), there was no fluorescence and the diagnosis of gastric cancer was excluded (false-positive results were not registered). Of 7 patients with Barrett's esophagus, fluorescence was noted in 3 during video fluorescence investigations. Histological study revealed a severe degree of dysplasia, tumor growth was not found.

The following results were obtained using the double-channel system: distinct glow was noted in 1 patient with gastric cancer and in 1 with malignant polyp, in 2 patients with gastric cancer, the fluorescence has not been registered distinctly because of massive superficial tumor necrosis and blood admixture in the stomach.

Performing intraoperative/laparoscopic examination with the help of the single-channel system, fluorescence was observed in those cases when the tumor invaded the serous coat of the stomach or infiltrated adjacent organs and tissues (in the presence of canceromatosis). These changes were noted in 8 observations. If there was no invasion of the tumor through all the stomach layers, fluorescence was not registered (4 observations), in 2 cases the results were assessed as equivocal: fluorescence was not seen distinctly (the histological study showed that the tumor grew into the subserous membrane but no invasion of the serous



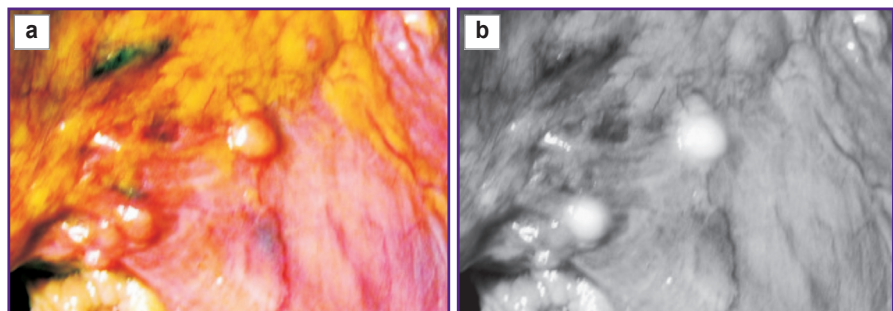
**Figure 3. Diagram of image formation in the double-channel version of the fluorescence diagnostic video system**

**Video fluorescence investigations of the stomach and esophagus**

Type of investigation	Investigations (n=57)			
	Endoscopic (n=39)		Intraoperative/laparoscopic (n=18)	
Type of video system	Single-channel (n=35)	Double-channel (n=4)	Single-channel (n=15+7 additional investigations on a macropreparation)	Double-channel (n=3)
<i>Disease (number of patients) and presence (+) or absence (-) of fluorescence</i>				
Gastric cancer	24 (+21, -3)	3 (+1, -2)	15 (+9, -4, 2 — equivocal result)	3 (-3)
Chronic atrophic gastritis	1 (-1)	—	—	—
Stomach polyp	1 (-1)	—	—	—
Barrett's esophagus	7 (+3, -4)	—	—	—
Ulcer disease	2 (-2)	—	—	—
Malignant polyp	—	1 (+1)	—	—

**Figure 4. Patient B., cancer of the stomach; abdominal cavity examination at laparoscopy**

Metastatic damage of lymphatic nodes along the greater curvature of the stomach is revealed; (a) image in the visible light; (b) video fluorescence image



coat was noted). In one patient, the tumor did not grow into the serous coat but metastases in regional lymph nodes fluorescence of which was distinctly registered were detected (Figure 4). When examining 7 macropreparations, distinct fluorescence was noted in 1 observation, in other cases it was either absent or was considered equivocal.

When the updated double-channel system was applied at laparoscopy in the patient with serous membrane invasion and massive peritoneum canceromatosis, no fluorescence was present. The reason was in the stent that had been installed for subcompensated stenosis that led to rapid evacuation of 5-ALA from the stomach and failure to absorb it. In 2 intraoperative examinations, fluorescence was not registered as there was no serous membrane invasion. Video fluorescence investigations on macropreparations were not conducted.

**Discussion**

In recent decades, rapid development of endoscopic technologies is observed. However, it is not simple in some cases to make a differential diagnosis between benign and malignant alterations in the stomach and to assess a real extension of the process during laparoscopy or intraoperatively. This situation encourages the development of novel technologies and improvement of the existing ones. One of the most

promising methods for solving this problem is laser video and spectrofluorescence diagnosis. Spectral fluorescence diagnostic procedure only insignificantly increases the time of esogastroduodenoscopy (in contrast to chromoendoscopy), laparoscopy, or operation but the opinion on the character of the pathological process may be obtained immediately in the course of the examination. The apparatus complex used for fluorescence diagnosis is sufficiently compact and mobile irrespective of system modification.

The method of spectral video fluorescence diagnosis is indicated in difficult diagnostic situations when gastric cancer is suspected, and owing to its relative simplicity and safety is expected to become a standard stage of endoscopic examination in future. It is not reasonable to employ fluorescence methods for investigating patients with a definitely established diagnosis of stomach cancer and when total-subtotal damage of the organ is suspected because of the problems with drug absorption. Besides, massive necrotic changes on the tumor surface in advanced cancer stages make it impossible to perform adequate spectral and video fluorescence diagnosis. At the same time, if tumor growth is mainly of submucous character and standard endoscopic examination and biopsy data are not informative enough, fluorescence diagnosis may serve as a very effective method of investigation.

Investigation of video fluorescence with the application of 5-ALA-induced PP IX may be recommended for use

in clinics as an express method of diagnosis including early diagnosis of malignant stomach diseases as well as for intraoperative assessment of tumor extension, and detection of canceromatous foci during laparoscopy.

## Conclusion

Registration of video fluorescence using the developed analyzers of fluorescence images enables surgeons to conduct differential express diagnosis of stomach diseases with a high degree of accuracy, to make early diagnosis of cancer and to reveal precancer conditions. The first experience of using video fluorescence diagnosis of gastric cancer with the help of 5-ALA Alasens preparation has demonstrated its sufficiently high diagnostic value and promising perspectives. Enhancement of sensitivity of the suggested methodology and improvement of image quality will allow to create production samples of the equipment and promote implementation of the method into a wide clinical practice.

**Study funding.** The work was not supported by any sources.

**Conflicts of interest.** The authors have conflicts of interest.

## References

1. Marqués-Lespier J.M., González-Pons M., Cruz-Correa M. Current perspectives on gastric cancer. *Gastroenterol Clin North Am* 2016; 45(3): 413–428, <https://doi.org/10.1016/j.gtc.2016.04.002>.
2. Waddingham W., Graham D., Banks M., Jansen M.F. The evolving role of endoscopy in the diagnosis of premalignant gastric lesions. *F1000Res* 2018; 7: 715, <https://doi.org/10.12688/f1000research.12087.1>.
3. Sokolov V.V., Chissov V.I., Filonenko E.V., Telegina L.V., Trakhtenberg A.Kh., Frank G.A., Bulgakova N.N. Fluorescence detection of early central lung cancer. *Pul'monologia* 2005; 1: 107–116.
4. Yagudaev D.M., Sorokaty A.E., Martov A.G., Heinits A.V., Markova M.V. Photodynamic therapy of prostatic adenoma. *Urologia* 2007; 4: 34–37.
5. Tsyb A.F., Kaplan M.A., Molochkov V.A., Mironov A.F., Romanko Yu.S., Kapinus V.N., Tretyakova Ye.I., Sukhova T.Ye. Use of photodynamic therapy in the treatment of solitary and multiple basal-cell carcinomas. *Rossiiskij zurnal koznyh i venericheskikh boleznej* 2000; 4(10): 4–12.
6. Novikova E.G., Trushina O.I., Sokolov V.V., Filonenko E.V. Fluorescent diagnosis and photodynamic therapy of pretumor pathology and an initial form of uterine cervix cancer. *Rossiiskij onkologicheskij zurnal* 2005; 6: 28–33.
7. Yagudajev D.M., Geinitz A.V., Martov A.G., Sorokaty A.E. The first results of PDT used for urinary bladder cancer. *Lazernaja medicina* 2004; 8(3): 242.
8. Loschenov V.B., Linkov K.G., Savelieva T.A., Loschenov M.V., Model S.S., Borodkin A.V. Hardware and tool equipment for fluorescence diagnostics and photodynamic therapy. *Fotodinamicheskaya terapiya i fotodiagnostika* 2013; 3: 17–25.
9. Chen W.R., Jassemnejad B., Crull J., Knobbe E.T., Nordquist R.E. Detection and characterization of chemical-induced abnormal tissue and rat tumors at different stages using fluorescence spectroscopy. *Proc. SPIE 2679, Advances in Laser and Light Spectroscopy to Diagnose Cancer and Other Diseases III: Optical Biops* 1996, <https://doi.org/10.1117/12.237570>.
10. Cheng C.W., Lau W.K., Tan P.H., Olivo M. Cystoscopic diagnosis of bladder cancer by intravesical instillation of 5-aminolevulinic acid induced porphyrin fluorescence — the Singapore experience. *Ann Acad Med Singapore* 2000; 29(2): 153–158.
11. Curnow A., Mclroy B.W., Postle-Hacon M.J., Porter J.B., MacRobert A.J., Bown S.G. Enhancement of 5-aminolevulinic acid-induced photodynamic therapy in normal rat colon using hydroxypyridinone iron-chelating agents. *Br J Cancer* 1998; 78(10): 1278–1282, <https://doi.org/10.1038/bjc.1998.671>.
12. Campbell D.L., Gudgin-Dickson E.F., Forkert P.G., Pottier R.H., Kennedy J.C. Detection of early stages of carcinogenesis in adenomas of murine lung by 5-aminolevulinic acid-induced protoporphyrin IX fluorescence. *Photochem Photobiol* 1996; 64(4): 676–682, <https://doi.org/10.1111/j.1751-1097.1996.tb03123.x>.
13. Battersby A.R., Fookes C.J., Matcham G.W., McDonald E. Biosynthesis of the pigments of life: formation of the macrocycle. *Nature* 1980; 285(5759): 17–21, <https://doi.org/10.1038/285017a0>.
14. Shemin D., Russell C.S.  $\delta$ -aminolevulinic acid, its role in the biosynthesis of porphyrins and purines. *J Am Chem Soc* 1953; 75(19): 4873–4874, <https://doi.org/10.1021/ja01115a546>.